

## DERMATOFIBROMA OF THE FOOT MIMICKING NEUROFIBROMA RADIOLOGICALLY

Agunloye A.M , Atalabi O.M , Ogunseyinde A.O, Obajimi M.O. and Adeyinka A.O.  
Department of Radiology, University College Hospital , Ibadan.

### Corresponding Author:

Dr Agunloye A.M  
Department of Radiology  
University College Hospital, Ibadan  
[tinuagunloye@comui.edu.ng](mailto:tinuagunloye@comui.edu.ng) ; [tinuagunloye@yahoo.com](mailto:tinuagunloye@yahoo.com)

### INTRODUCTION

Dermatofibroma also known as benign fibrous histiocytoma (BFH) or sclerosing haemangioma is a rare benign neoplastic tumor of the skin which usually occurs in young adults<sup>1</sup>. There is no sex predilection. 20% of patients have a history of previous trauma and the extremities are affected in 80% of cases<sup>2</sup>. Lesions are, however, rare on the soles of the feet<sup>3</sup>.

Presented below is the case of dermatofibroma of the foot in a 21 year old man in whom a radiological diagnosis of the more common plexiform neurofibromatosis of the foot was initially made. However, histology revealed the correct diagnosis.

This case report is aimed at raising the awareness of clinicians and radiologists, so that dermatofibroma can be included in the list of differentials when a diagnosis of plexiform neurofibromatosis of the foot is being considered.

### CASE REPORT

A.O. is a 21 year old secondary school student who presented at the surgical outpatient department of the University College Hospital, Ibadan with 1½ year history of swelling of the right foot. The foot has slowly increased in size over this period and there was associated pain and itching. No history of preceding trauma was elicited and there was no discharging sinus.

On clinical examination, a multilobulated bony hard swelling measuring 15x20cm was found in the distal half of the dorsum of the right foot overlying the 2<sup>nd</sup> and 3<sup>rd</sup> toes. The other systems were essentially normal. A provisional diagnosis of

enchondroma was made.

Radiographs of the foot (Fig 1) showed an increase in the soft tissue of the plantar aspect of the forefoot with widening of the intermetatarsal and interphalangeal spaces. There was obliteration of the marrow spaces in a greater portion of the shafts of the 2<sup>nd</sup>, 3<sup>rd</sup> and 4<sup>th</sup> metatarsals. The involved metatarsals also had a wavy flattened ribbon like appearance. The 1<sup>st</sup> metatarsal was bowed with media concavity. The 3<sup>rd</sup> metatarsophalangeal joint also showed some degree of subluxation. A radiological diagnosis of the plexiform type of neurofibromatosis was made.

A fine needle aspiration biopsy and cytology of the mass showed it to be a spindle cell tumour. A wedge biopsy was later done and the histologic findings were consistent with Dermatofibroma or Benign fibrous histiocytoma.

Unfortunately, the patient developed generalised tetanus with the portal of entry probably being the surgical wound. He however recovered and was discharged home. He is scheduled for total excision of the tumor at a later date.

### DISCUSSION

Dermatofibroma or BFH usually presents as a small (less than 1cm) firm, painless nodule in the skin<sup>2</sup> which may be single or multiple. This patient presented after a long duration and the tumor was quite large at presentation. Occasionally, dermatofibromas may be more deeply situated in the soft tissue. In white races or light colored blacks, the skin over the lesion is usually reddish brown but it may be dark in colour. It could also be black due to heavy deposition of hemosiderin. It may then be mistaken for malignant melanoma. Clinically,

the firm consistency of dermatofibroma and presence of a central dimple on lateral compression is a useful clinical sign in differentiating it from melanoma<sup>4</sup>.

A history of a skin puncture or insect bite prior to onset of the lesion may be elicited but this was absent in our patient. The diagnosis of dermatofibroma can usually be made clinically and no treatment is required unless the lesion is large or causing discomfort<sup>1</sup>. With a large tumor, as in this patient, radiological differentiation between BFH and neurofibromatosis is not possible as both may result in localised gigantism. Skeletal deformity due to cortical pressure resorption from the soft tissue tumor mass is also seen in both cases<sup>5</sup>. Radiographically, this is seen in the bones as cortical thinning, overtubulation, bowing and erosive cortical defects. Most of these changes were seen on this patient's radiograph. The plain radiograph is usually sufficient to suggest a diagnosis of neurofibromatosis, which is commoner. However, the diagnosis of neurofibromatosis can be more reliably made in patients with plexiform neurofibroma if any one or more of the following classic criteria are also

present: (i) six or more café-au-lait spots (ii) two or more neurofibromas (iii) axillary freckling (iv) iris hamartomas - Lisch nodules (v) optic glioma and (vi) one or more first degree relatives with neurofibromatosis since it may have an autosomal dominant (AD) inheritance<sup>6</sup>.

Histologically, dermatofibroma is made up of fibroblasts, histiocytes, capillaries and young or mature collagen in varying proportions. The collagen fibers are typically arranged in an intertwined mat-like pattern or radiate from a central point in a whorled arrangement<sup>7</sup>. The overlying epidermis is hyperplastic in 80% of cases<sup>8</sup>. However, the absence of nerve fibers distinguishes it from neurofibroma which is a commoner fibrous tumor arising in nerve roots. With a large tumor as in this patient, treatment is by total excision.

#### REFERENCES

1. Revell PA, Sommerlad FC. In: The foot, edited by Basil Hetal and Derek Wilson; Churchill Livingstone, Edinburgh 1985; 741-750.
2. William A Caro. In: Dermatology, edited by Moschella . S. L., Pillsbury D.M. and Hurley HJ, WB. Saunders Company, Philadelphia, 1975; 1368-1370.
3. Bedi TR, Paudhi RK, Rhutania LK. Multiple Palmo-plantar histiocytomas. Arch. Dermatol, 1976; 112: 1001-1003.
4. Fitzpatrick TN, Gilchrist BA. Dimple sign to differentiate benign from malignant pigmented cutaneous lesions. New England J. Med. 1977; 296: 1518.
5. Greenfield GB. Radiology of bone disease, 3rd edition. J.B. Lippincott Company, Philadelphia and Toronto 1980; pp 325-329.
6. Chapman S Nakielny. Aids to Radiological Differential Diagnosis, 3<sup>rd</sup> edition. W.B. Saunders Company Limited 1995; pp 565-567.
7. Gross RE, Wolbach SD. Sclerosing hemangiomas: Their relationship to dermatofibroma, histiocytoma, xanthoma and to certain pigmented lesions of the skin. Am. J. Pathol. 1943; 19: 533-551.
8. Schoenfeld RJ. Epidermal proliferations overlying histiocytomas Arch. Dermatol 1964; 90: 266-270.

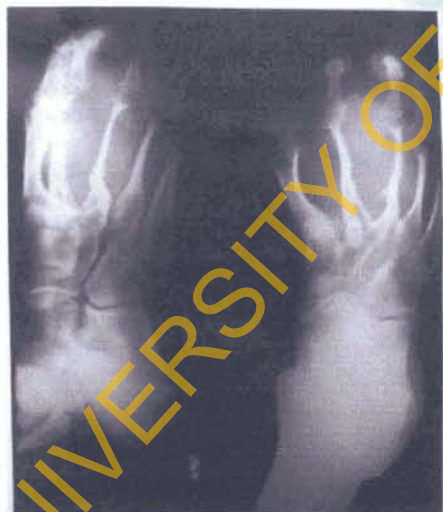


Fig 1  
Antero-posterior and oblique radiographs of the right foot. There is splaying and attenuation of the metatarsals and encasement of the 2<sup>nd</sup>, 3<sup>rd</sup> and 4<sup>th</sup> metatarsals by a soft tissue mass.