



The Egyptian German Society for Zoology  
The Journal of Basic & Applied Zoology

www.egsz.org  
www.sciencedirect.com



## Ameliorative effects of *Musa sapientum* peel extract on acetic acid-induced colitis in rats



Gbemisola A. Adegoke<sup>a</sup>, Samuel A. Onasanwo<sup>a</sup>, O. David Eyarefe<sup>a,b</sup>,  
Samuel B. Olaleye<sup>a,\*</sup>

<sup>a</sup> Department of Physiology, Faculty of Basic Medical Science, College of Medicine, University of Ibadan, Ibadan, Nigeria

<sup>b</sup> Department of Clinical Studies, School of Veterinary Medicine, Kwame Nkrumah University of Science and Technology, Ghana

Received 6 November 2015; revised 18 May 2016; accepted 5 June 2016

Available online 14 November 2016

### KEYWORDS

*Musa sapientum* (MS) peel;  
Colitis;  
Plant extract;  
Acetic acid;  
Sulfasalazine

**Abstract** Ameliorative effects of *Musa sapientum* peel extract (MSPE) were studied on Acetic Acid (AA)-induced colitis in rats. From a dose response study, the effective and yet, safe for the treatment of AA-induced colitis in rats was determined, and also, a further study was carried out to determine the effective fraction(s) of MSPE that will be useful in the treatment of AA induced colitis in rats. Colitis was induced with 0.2 ml of 6% acetic acid through a lower abdominal laparotomy. Treatment with graded doses of methanolic extract of dried peel of *Musa sapientum* (MS) (50, 100 and 200 mg/kg) for 7 days in AA induced colitis in rats showed 50 mg/kg as an optimal effective dose for the healing of AA induced colitis in rats. This dose (50 mg/kg) was further studied with fractions of MSPE in comparison to a standard drug (sulfasalazine) of the same dose (50 mg/kg) on AA induced colitis in rats for 18 days. Colitis was assessed using stool consistency, macroscopic gross score and histological studies. Normal stool consistency was seen early in treated animals as compared with control; MS peel (crude extracts and fractions) significantly reduced macroscopic and histologic colon tissue damage in a manner similar to that of sulfasalazine. The results from these findings suggests that MSPE fractions of ethyl acetate and methanol may be effective in reducing both macroscopic and histological damage in a manner similar to sulfasalazine, and that it may be helpful in the treatment of colitis.

© 2016 The Egyptian German Society for Zoology. Production and hosting by Elsevier B.V. This is an open access article under the CC BY-NC-ND license (<http://creativecommons.org/licenses/by-nc-nd/4.0/>).

### Introduction

Ulcerative colitis is a form of colitis which presents with characteristic ulcers, or open sores (Ahmad et al., 2014) as a result of chronic inflammation of the bowel, its cause is unknown but it exhibits a clinical course with remission and exacerbations

(Sellin and Pasricha, 2006; Podolsky and Fiocchi, 2000; Podolsky, 1991). It is characterized by abdominal pain, rectal bleeding and diarrhea and it primarily affects the colon and rectum (Podolsky, 1991) with an incidence of 1–20 cases per 100,000 persons in a year, and a prevalence of 8–246 per 100,000 persons (Danese and Fiocci, 2011).

There are no effective therapies presently to cure the disease, although treatment regimens depend on reduction of abnormal inflammation in the colon lining thereby reducing

\* Corresponding author.

Peer review under responsibility of The Egyptian German Society for Zoology.

<http://dx.doi.org/10.1016/j.jobaz.2016.06.004>

2090-9896 © 2016 The Egyptian German Society for Zoology. Production and hosting by Elsevier B.V.

This is an open access article under the CC BY-NC-ND license (<http://creativecommons.org/licenses/by-nc-nd/4.0/>).

the symptoms of diarrhea, rectal bleeding, and abdominal pain (Ahmad et al., 2014). However, *Musa sapientum* has been shown to be medicinal and useful in the maintenance of bowel functions (Goel and Sairam, 2002; Kumar et al., 2012).

*Musa sapientum* L. (Family: *Musaceae*), is commonly known as “banana”. It is a perennial fruit tree that grows in the tropics, with a height of about 5–9 m; it is made of a hard, long pseudo-stem, and inflorescence with a reddish brown bract. The fruits, leaves, peels, root and stalks of banana plants are used orally or topically in the management of diarrhea, dysentery, intestinal lesions, and hypoglycemia in local settings (Stover and Simmonds, 1987).

*Musa sapientum* (MS) pulp used in *in vitro* work of animal model, and limited human studies suggests that it may be beneficial in the treatment of ulcerative colitis because of its phytochemical content (Shah, 2007), MS peel however, has more phytochemicals than its pulp (Someya et al., 2002; Kondo et al., 2005; Sulaiman et al., 2011). Conventional therapies for ulcerative colitis include amino salicylates, corticosteroids, and immunosuppressive medications, these however do not cure the condition but rather, they focus on producing and maintaining remission (Podolsky, 2002; Forbes et al., 2004; Baumaqart and Sandborn, 2007; Ahmad et al., 2014). Sulfasalazine and other 5-ASA drugs aim at scavenging reactive oxygen species, but these synthetic drugs have been associated with some complications and side effects on prolonged use; this is why medicinal plants are being considered as alternative therapies, especially those that have been found to possess antioxidant properties.

The peels of *Musa sapientum* are natural and have been found to possess antioxidant properties (Imam et al., 2011) probably due to its flavonoidal and polyphenolic content, also, Onasanwo et al. (2013) reported that people of the southwestern Nigeria, blend dried banana peel with yam flour to make one of their main meals and that folk people say this meal ameliorates gastric disorders. Moreover, studies have reported the beneficial effects of antioxidants on experimental colitis (Nosal'ova et al., 2000; Gulluoglu et al., 1999; Kaya et al., 1999), antioxidants from plant sources like the *Musa sapientum* peel are therefore being considered for the management of colitis. This work was carried out to explore the ameliorative effect of *Musa sapientum* peel extract on experimental colitis in rats.

## Materials and methods

### Chemicals and reagents

Methanol, n-hexane, ethyl-acetate, ketamine, xylazine, acetic acid, tween 20 and sulfasalazine.

### Plant materials and extraction

Fresh peels (2.0 kg) of *Musa sapientum* (MS) were collected, air-dried during harmattan (between November and December) and authenticated at Forestry Research Institute of Nigeria (FRIN), Ibadan, Nigeria, where the Voucher Specimen No: 109540 was deposited. The dried peels of MS were milled to make a coarse powder. A part was refluxed with 90% methanol to get the crude extract and the other part was fractionally extracted with 100% n-hexane, ethyl acetate and methanol

consecutively. MS peel was fractionated in order to easily identify the part(s) containing the active components through properties of the solvents used to carry out the extraction.

### Animals

Albino rats of the Wistar strain weighing between 150 and 180 g were used for the experiment. The animals were acclimatized for two weeks and kept under standard conditions (37°C) in the Animal facility of the College of Medicine, University of Ibadan, with food and water made accessible freely.

### Experimental design

This experiment had an initial dose response study in which rats were divided into four groups. Group 1 received the vehicle (distilled water and 0.25 Tween 20); group 2 received 50 mg/kg of MS peel extract; group 3 received 100 mg/kg of MS peel extract; and group 4 received 200 mg/kg of MS peel extract orally once daily for 7 days post induction of colitis. A further study was carried out thereafter, with extracts of MS fractions on acetic acid-induced colitis in which rats were divided into five groups. The dosage that presented with no obvious side effect (50 mg/kg) of the three dosages (50, 100 and 200 mg/kg) and still showed healing potential in the initial study was selected as the effective dose. Group 1 received the vehicle (distilled water and 0.25 Tween 20) only; group II received 50 mg/kg n-hexane fraction of the extract; group III received 50 mg/kg ethyl acetate fraction of the extract; group IV received 50 mg/kg methanol fraction of the extract; group V received a standard drug (Sulfasalazine, 50 mg/kg) orally once daily for 18 days post induction of colitis.

### Induction of colitis

Rats were deprived of food for 18 h before colitis induction, they were anesthetized with an intramuscular injection of 5% ketamine (35.0 mg/kg) and 2% xylazine (5.0 mg/kg) and the colon was approached through a ventral midline incision as earlier described (Eyarefe and Amid, 2010; Uchida and Mogami, 2005). The colon was exteriorized, clipped with an eye forceps of 8 mm eye diameter, and 0.2 ml of 6% acetic acid solution was injected into the colon lumen at the area limited by the eye forceps, and the solution was withdrawn after 45 s with the same injection syringe and needle. The colon was returned into the abdominal cavity and the laparotomy incision was closed. Acetic acid model of colitis is an easy and common method which has some resemblance to acute intestinal inflammation in humans (Fabia et al., 1992).

### Treatment schedules

Treatment commenced on the 3rd day of colitis induction and it continued for 7 days by oral administration of graded doses of the crude methanol extract of MS peel (50, 100, and 200 mg/kg) for the initial dose response study, this was done to test the efficacy and dosage of MS peel extract that will attenuate AA-induced colitis in experimental rats. Also, in the further study, treatment commenced on the 3rd day of colitis induction and it continued till 21st day by oral adminis-

tration of three different fractions (50 mg/kg) of MSPE and Sulfasalazine (50 mg/kg), once daily to appropriate animal groups.

#### Assessment of colitis formation

In the initial dose response study, rats from each group were sacrificed on the 3rd, 7th and 10th day of colitis induction and also, in the further study on the 3rd, 7th, 14th and 21st day of colitis induction. Colons were removed, cleared of fecal content by rinsing in normal saline, analyzed macroscopically and thereafter, fixed in 10% formalin for histological assessment.

#### Stool consistency scoring

To assess the extent of colitis, stool consistency and occult blood in the stool was monitored and scored daily (Masonobi et al., 2002), with slight modifications as follows: 0-(normal/negative hemocult), 1-(soft but still formed/positive hemocult), 2-(very soft/blood traces in stool visible), 3-(diarrhea/rectal bleeding).

#### Macroscopic scoring of colitis

Colon of animals were removed, cut longitudinally and slightly cleaned in normal saline to remove fecal residues. Macroscopic inflammation scores were assigned based on the grading scale (Morris et al., 1989), ranging from 0 to 4 as follows: 0-(no ulcer), 1-(mucosal erythema only), 2-(Mild mucosal edema, bleeding ulcers or erosions), 3-(Moderate mucosal, bleeding

ulcers or erosions), 4-(Severe ulcerations, erosions, edema, tissue necrosis and perforations).

#### Histological studies

Colonic segments fixed in 10% formalin were embedded in paraffin and cut into sections, this was then de-paraffinized with xylene, hydrated and stained with hematoxylin and eosin. Stained sections were assessed for inflammatory changes.

#### Statistical analysis

Analysis of data was performed using a statistical software-graph pad prism (version 5.0). Results were expressed as mean  $\pm$  S.E.M, statistical significance was assessed using one-way analysis of variance (ANOVA) followed by Newman-Keuls multiple comparison test. Differences were considered significant at \* $P < 0.05$ , \*\* $P < 0.01$  and \*\*\* $P < 0.001$ .

## Results

#### Stool consistency assessment

The stool consistency results as seen in Tables 1 and 2 showed that there were relapses in the stool consistency of all the groups in both the dose response and further study. Normal stool consistency was later established and maintained till the end of the experiment.

**Table 1** Stool consistency for initial dose response study.

Groups	Dose	Scoring				
		Day1	Day2	Day3	Day5	Day6
Control	Water	0.11 $\pm$ 0.11	0.33 $\pm$ 0.17	0.44 $\pm$ 0.18	0.33 $\pm$ 0.21	0.17 $\pm$ 0.17
50 mg/kg of MS extract	50 mg/kg	0.22 $\pm$ 0.15	0.11 $\pm$ 0.11	0.33 $\pm$ 0.17	1.50 $\pm$ 0.34*	1.50 $\pm$ 0.34*
100 mg/kg of MS extract	100 mg/kg	0.56 $\pm$ 0.18	0.78 $\pm$ 0.15	0.56 $\pm$ 0.34	0.67 $\pm$ 0.21	1.50 $\pm$ 0.50*
200 mg/kg of MS extract	200 mg/kg	0.22 $\pm$ 0.15	1.22 $\pm$ 0.28**	1.44 $\pm$ 0.18*	0.83 $\pm$ 0.17	1.17 $\pm$ 0.17*

Values were expressed as mean  $\pm$  S.E.M of 5 rats.

\*\*\*  $p < 0.001$ .

\*  $p < 0.05$ .

\*\*  $p < 0.01$ .

**Table 2** Stool consistency for further study.

Groups	Dose	Scoring					
		Day7	Day9	Day11	Day12	Day13	Day14
Control	Water	0.83 $\pm$ 0.24	1.58 $\pm$ 0.36	2.87 $\pm$ 0.13	2.63 $\pm$ 0.38*	2.63 $\pm$ 0.38	1.88 $\pm$ 0.23
N-hFMS	50 mg/kg	1.75 $\pm$ 0.22	0.50 $\pm$ 0.19	1.63 $\pm$ 0.42**	1.38 $\pm$ 0.42*	1.25 $\pm$ 0.37*	1.38 $\pm$ 0.38
EAFMS	50 mg/kg	0.75 $\pm$ 0.22	1.33 $\pm$ 0.23	0.88 $\pm$ 0.23***	0.88 $\pm$ 0.23**	0.38 $\pm$ 0.18***	0.0 $\pm$ 0.0***
MFMS	50 mg/kg	1.83 $\pm$ 0.21*	1.25 $\pm$ 0.18*	2.25 $\pm$ 0.31	1.50 $\pm$ 0.46*	1.38 $\pm$ 0.46*	0.88 $\pm$ 0.40*
Sulfasalazine	50 mg/kg	1.00 $\pm$ 0.25*	0.58 $\pm$ 0.23*	1.00 $\pm$ 0.19***	1.25 $\pm$ 0.16	0.50 $\pm$ 0.27***	0.13 $\pm$ 0.13***

Values were expressed as mean  $\pm$  S.E.M of 5 rats.

\*  $p < 0.05$ .

\*\*  $p < 0.01$ .

\*\*\*  $p < 0.001$ .

### Macroscopic assessment

MSPE significantly reduced mean gross score of macroscopic colon morphology on day 7 in the 50, 100 and 200 mg/kg treated groups of the dose response and further study, significant reduction was noticed in colon macroscopic gross score on day 7 in ethyl acetate, methanol fraction of MSPE and sulfasalazine treated groups when compared with control as shown in Tables 3 and 4.

### Histological assessment

Histological studies as seen in Plates. 1 and 2 show lymphocyte infiltration, edematous sub-mucosa and transmural inflammation at days 3, 7 and day 10 in all the groups for the initial dose response study. In the further study, lymphocyte infiltration of the mucosa was observed at days 3, 7, in all the groups but as at day 14, recovery had started in n-hexane, ethyl acetate, methanol MSPE fraction-treated groups, and sulfasalazine-





treated group. By day 21, relatively normal structure with intact mucosa and submucosa was seen in methanol, ethyl acetate fraction treated, and sulfasalazine-treated groups as compared with control group in which inflammation was still evident.

### Discussion

In this study, colitis was induced with acetic acid and this resulted in a severe, deep ulcer on a particular spot of the colon with high infiltration of inflammatory aggregates, and diarrhea was evident in all the rats after induction of colitis. These may be due to the damaging effects of AA on the colonic mucosa, as well as alterations in the functions of the epithelium either by the mast cells or their by-products. Such alterations in the intestinal barrier function by mast cells and their products during experimental colitis were reported by Stein et al. (1998).

Relapses observed in the stool consistency of all the groups in both the dose response and further study is a common

**Table 3** Mean macroscopic score of rats' colon at different days in colitis for the initial dose-response study.

Treatment	Scoring			
	Day3	Day7	Day7 Gross	Day10
Control	3.33 ± 0.333	2.33 ± 0.333		1.67 ± 0.333
50 mg/kg of MS extract	3.33 ± 0.333	0.67 ± 0.333*		0.67 ± 0.333
100 mg/kg of MS extract	3.67 ± 0.333	0.67 ± 0.333*		0.33 ± 0.333
200 mg/kg of MS extract	3.33 ± 0.333	0.67 ± 0.33**		1.00 ± 0.577






Values were expressed as mean ± S.E.M of 5 rats.

\*\*\*  $p < 0.001$ .

\*  $p < 0.05$ .

\*\*  $p < 0.01$ .

**Table 4** Mean macroscopic score of rats' colon at different days in colitis for the further study.

Groups	Dose	Scoring				
		Day3	Day7	Day7 Gross	Day14	Day21
Control	Water	3.50 ± 0.289	1.75 ± 0.250		0.25 ± 0.250	0.00 ± 0.000
N-hFMS	50 mg/kg	3.25 ± 0.250	1.25 ± 0.250		0.00 ± 0.000	0.00 ± 0.000
EAFMS	50 mg/kg	3.75 ± 0.250	0.50 ± 0.289**		0.00 ± 0.000	0.00 ± 0.000
MFMS	50 mg/kg	3.50 ± 0.289	0.00 ± 0.000***		0.00 ± 0.000	0.00 ± 0.000
Sulfasalazine	50 mg/kg	3.50 ± 0.289	0.00 ± 0.000***		0.00 ± 0.000	0.00 ± 0.000

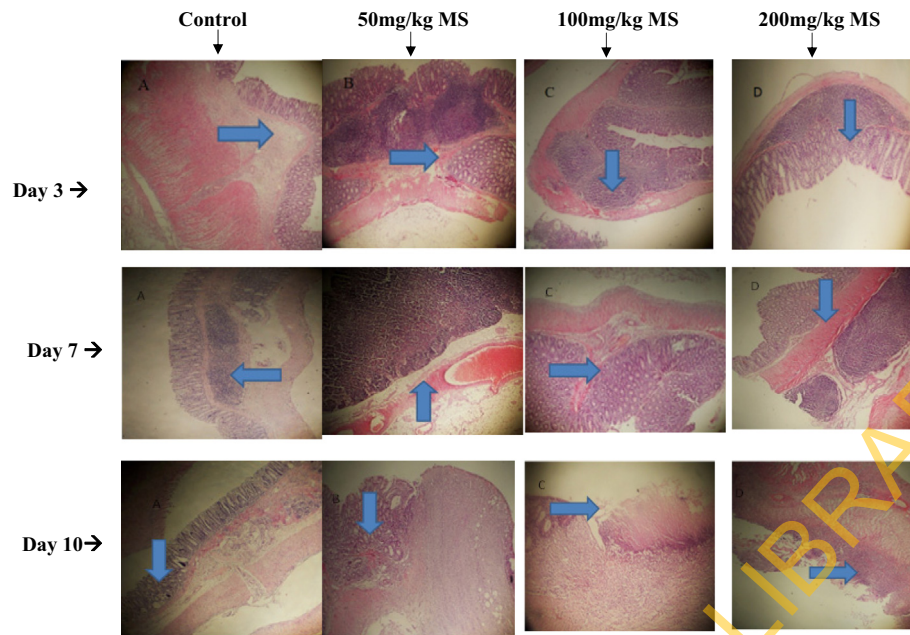
Values were expressed as mean ± S.E.M of 5 rats.

\*  $p < 0.01$

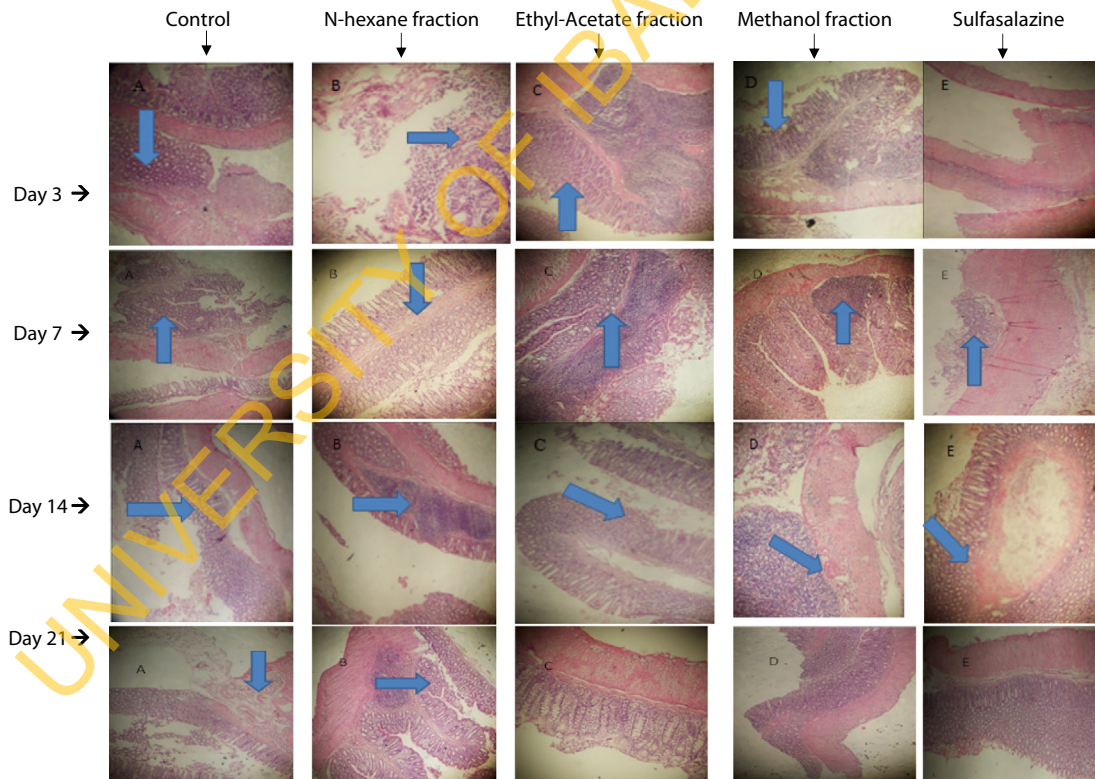
\*\*  $p < 0.05$ .

\*\*\*  $p < 0.001$ .





**Plates. 1** Photomicrographs from colon sections of untreated (control) rats and those treated with 50, 100 and 200 mg.kg of crude extracts of *Musa sapientum* peel extract before induction of colitis by acetic acid. Tissues were harvested on days 3, 7 and 10 after colitis induction. Arrows show different levels of lymphocyte infiltration of the mucosa, hemorrhage and edema.



**Plates. 2** Photomicrographs from colon sections of untreated (control) rats and those N-hexane, Ethyl acetate and Methanol fractions of *Musa sapientum* as well as Sulfasalazine (standard drug) before induction of colitis by acetic acid. Tissues were harvested on days 3, 7 and 14 and 21 days after colitis induction. In the slides where there were no arrows, no signs of lymphocyte infiltration of the mucosa, hemorrhage and edema were seen.

finding in Ulcerative Colitis. Normal stool consistency was however, observed and maintained earlier in treated groups till the end of the experiment, this may be due to the fact that only a little portion of the colon was affected and also, probably due to the effects of MSPE administration. MS pulp have been reported to possess antidiarrheal properties (Khare, 2007; Ghani, 2003), intestinal transit period may have increased in the treated groups thus, providing more time for absorption. Similar increased transit period in mice was reported by Hossain et al. (2011) when they administered 100 and 200 mg/kg MS.

MSPE significantly reduced mean gross score of macroscopic colon morphology in treated groups of the dose response and further study; methanol and ethyl acetate fractions of MSPE showed similar effects as sulfasalazine. This may be attributed to MSPE and its fractions on mucosal defensive factors as Sanyal et al. (1963) and Kumar et al. (2012) reported the antiulcer effect of banana in pylorus ligation and AA induced model of ulcer in rats respectively, this they attributed to its predominating effect on mucosal defense factors including enhanced cell proliferation and antioxidants and reducing free radicals levels.

Photomicrographs of the histological studies showed that inflammation, ulcer and edema reduced earlier in methanol, ethyl acetate and n-hexane fraction of MS peel-treated groups, and sulfasalazine treated group. Full recovery was noticed earlier in the methanol and ethyl acetate fraction treated groups in a similar manner to sulfasalazine treated group, this was evident by an intact mucosa which may be due to MSPE's antioxidant activity. MS has been found with antioxidant activity that gives it ability to scavenge free radicals and reduce inflammation (Imam et al., 2011).

MSPE may have also acted by inhibiting autacoids and prostaglandins, thereby reducing motility and hence, increasing intestinal transit period, leading to an increase in absorption of water and electrolytes in the colon (Lewis et al., 1999). Also, its flavonoid, serotonin and noradrenaline contents may have accorded it antidiarrheal and antioxidant potential (Kongkachuichai et al., 2010; Rabbani et al., 2001) through vasoconstriction and free radical scavenging. In conclusion, these findings showed that MS peel extract fractions of ethyl acetate and methanol may be effective in reducing both macroscopic and histological damage in a manner similar to the reference drug-sulfasalazine, and that it may be helpful in the treatment of colitis although its major protective components may be present in all the fractions; methanol, ethyl acetate and n-hexane of the extract. It is however obvious, that further studies would be required to identify its active components, the exact mechanism of its action and also, biochemical assays would be helpful in understanding the processes occurring during healing.

## References

- Ahmad, Bashir Ado, Rao, Mahadeva US, Muhammad, Abdurrazaq, Zin, Thant, Mohamad, Nur Hidayah, Mohamad, Nasir, Mohd, Khamsah Suryati, 2014. Reviews of herbal and their secondary metabolites in the treatment of ulcerative colitis and peptic ulcer. *J. Appl. Pharm. Sci.* 4 (08), 080–090.
- Baumaqart, D.C., Sandborn, W.J., 2007. Inflammatory bowel disease: clinical aspects and established and evolving therapies. *Lancet* 369, 1641–1657.
- Danese, S., Fiocchi, C., 2011. Ulcerative colitis. *New Engl. J. Med.* 365, 1713–1725.
- Eyarefe, O.D., Amid, S.A., 2010. Small bowel wall response to enterotomy closure with polypropylene and polyglactin 910 using simple interrupted suture pattern in Rats. *Int. J. Anim. Veter. Adv.* 2 (3), 72–75.
- Fabia, R., Willen, R., Ar'Rajab, A., Andersson, R., Ahren, B., Bengmark, S., 1992. Acetic acid-induced colitis in the rat: a reproducible experimental model for acute ulcerative colitis. *Euro. Surg. Res.* 24, 211–225.
- Forbes, E., Murase, T., Yang, M., Matthaei, K.I., Lee, J., Lee, A.N., 2004. Immunopathogenesis of experimental ulcerative colitis is mediated by eosinophil peroxidase. *J. Immunol.* 172, 5664–5675.
- Ghani, A., 2003. Medicinal Plants of Bangladesh: Chemical Constituents and Uses, second ed. The Asiatic Society of Bangladesh, Dhaka, Bangladesh.
- Goel, R.K., Sairam, K., 2002. Antiulcer drugs from indigenous sources with emphasis on *Musa sapientum*, *Tamrabhasma*, *Asparagus racemosus* and *Zingiber officinale*. *Ind. J. Pharmacol.* 34, 100–110.
- Gulluoglu, B.M., Kurtel, H., Gulluoglu, M.G., Yegen, C., Aktan, A. O., Dizdaroglu, F., Yalin, R., Yegen, B.C., 1999. Role of Endothelins in trinitrobenzene sulfonic acid-induced colitis in rats. *Digestion* 60, 484–492.
- Hossain, M.S., Alam, M.B., Asadujjaman, M., Zahan, R., Islam, M. M., Mazumder, M.E.H., Haque, E., 2011. Antidiarrheal, antioxidant and antimicrobial activities of the *Musa sapientum* seed. *Avicenna J. Med. Biotech.* 3 (2), 95–105.
- Kaya, E., Gur, E.S., Ozguc, H., 1999. L-glutamine enemas attenuate mucosal injury in experimental colitis. *Dis. Colon Rectum* 42, 1209–1215.
- Khare, C.P., 2007. Indian Medicinal Plants. Springer Science + Business Media, New York, USA, p. 426.
- Kondo, S., Kittikorn, M., Kanlayanarat, S., 2005. Preharvest antioxidant activities of tropical fruit and the effect of low temperature storage on antioxidants and jasmonates. *Postharvest Biol. Technol.* 36, 309–318.
- Kongkachuichai, R., Charoensiri, R., Sungpuag, P., 2010. Carotenoid, flavonoid profiles and dietary fiber contents of fruits commonly consumed in Thailand. *Int. J. Food Sci. Nutr.* 61 (5), 536–548.
- Kumar, M.M., Singh, A., Gautam, M.K., Goel, R.K., 2012. Role of cytokines and growth factor in gastric ulcer healing effects of unripe plantain banana (*Musa sapientum* var. *paradisica*). In: Ray, A., Gulati, K. (Eds.), In: *Translational Research in New Drug Development*, vol. 1. Vidyaniyam Prakashan, Delhi, India, pp. 269–284.
- Lewis, D.L., Field, W.D., Shaw, G.P., 1999. A natural flavonoid present in unripe plantain banana pulp (*Musa sapientum* L. var. *paradisica*) protects the gastric mucosa from aspirin-induced erosions. *J. Ethnopharmacol.* 65, 283–288.
- Masonobi, F., Osamu, K., Yoshio, A., Akira, A., Kehchi, M., Kohsuke, T., Atsushi, T., Michio, S., Yoshihide, F., Masamichi, F., Yoshiaki, M., Tadao, B., 2002. Prebiotic treatment of experimental colitis with germinated barley foodstuff; a comparison with probiotic or antibiotic treatment. *Int. J. Mol. Med.* 9, 65–70.
- Imam, M.Z., Saleha-Akter, M.D., Ehsanul, H.M., Sohel, R., 2011. Antioxidant activities of different parts of *Musa sapientum* L. ssp. *sylvestris* fruit. *J. Appl. Pharm. Sci.* 1 (10), 68–72.
- Morris, G.P., Herrigge, M.S., Depew, W.T., Szewczuk, M.R., Wallace, J.L., 1989. Hapten induced model of chronic inflammation and ulceration in the rat colon. *Gastroenterology*, 795–803.
- Nosal'ova, V., Cerna, S., Bauer, V., 2000. Effect of N-acetylcysteine on colitis induced by acetic acid in rats. *Gen. Pharm.* 35, 77–81.
- Onasanwo, S.A., Emikpe, B.O., Ajah, A.A., Elufioye, T.O., 2013. Anti-ulcer and ulcer healing potentials of *Musa sapientum* peel extract in the laboratory rodents. *Pharma. Res.* 5 (3), 173–178.
- Podolsky, D.K., Fiocchi, C., 2000. In: Kirsner, J.B. (Ed.), *Inflammatory Bowel Disease*, fifth ed. W.B. Saunders Company, Philadelphia, pp. 191–207.

- Podolsky, D.K., 2002. Inflammatory bowel disease. *New Engl. J. Med.* 347, 417–429.
- Podolsky, D.K., 1991. Inflammatory bowel disease. *New Engl. J. Med.* 325, 928–935.
- Rabbani, G.H., Teka, T., Zaman, B., Majid, N., Khatun, M., Fuchs, G.J., 2001. Clinical studies in persistent diarrhea: dietary management with green banana or pectin in Bangladeshi children. *Gastroenterology* 121, 554–560.
- Sanyal, A.K., Gupta, K.K., Chowdhury, N.K., 1963. Banana and gastric secretion. *J. Pharm. Pharmacol.* 15, 283–284.
- Sellin, J.H., Pasricha, P.J., 2006. Pharmacotherapy of inflammatory bowel diseases. In: Brunton, L.L., Lazo, J.S., Parker, K.L. (Eds.), *Goodman & Gilman's the Pharmacological Basis of Therapeutics*, 10th ed. McGraw-Hill Companies, New York, pp. 1009–1011.
- Shah, S., 2007. Dietary factors in the modulation of inflammatory bowel disease activity. *Med. Gen. Med.* 9 (1), 60.
- Someya, S., Yoshiki, Y., Okubo, K., 2002. *Food Chem.* 79, 351–354.
- Stein, J., Ries, J., Barret, K., 1998. Disruption of intestinal barrier function associated with experimental colitis: possible role of mast cells. *Am. J. Physiol.* 274, G274.
- Stover, R.H., Simmonds, N.W., 1987. *Bananas*, third ed.. Tropical Agriculture Series Longman.
- Sulaiman, F., Yusoff, M., Eldeen, M., Seow, M., Sajak, A., Supriatno, Ooi L., 2011. *J. Food Compos. Anal.* 24, 1–10.
- Uchida, M., Mogami, O., 2005. An improved and reliable method for the induction of colitis in rats using 2,4,6-trinitrobenzene sulfonic acid. *J. Pharmacol. Sci.* 97, 285–288.

UNIVERSITY OF IBADAN LIBRARY