

A Preliminary Report on Aural Hematoma Management with Auricular Pillow Method

¹O.D Eyarefe, ¹C.O. Oguntoye and ²B.O. Emikpe

¹Department of Veterinary Surgery and Reproduction, University of Ibadan, Ibadan, Nigeria

²Department of Veterinary Pathology, University of Ibadan, Ibadan, Nigeria

Abstract: *Background:* Aural hematoma management is associated with auricular cartilage scarification, pinna deformity and recurrence which are unacceptable dogs' owners. A simple management method with minimal anesthetic requirement and postoperative patient's stress, coupled with reasonable management cost and acceptable cosmetic outcomes is presented. *Method and findings:* Dogs presented at the Veterinary Teaching Hospital, University of Ibadan, Nigeria, with aural hematoma from January 2012-January 2013 were enrolled. Each hematoma was incised, drained and the pinna packed over cotton padded hard core as auricular pillow and supported with a non-adherent compression bandage over the head between 7-12 days. The surgical outcome of this method was compared with conventional methods used previously from 2002-2011 in the same hospital. The pinna healed with least scarification and restored morphology. The method has a comparative anesthetic, patient stress and cost advantages over other conventional methods. *Conclusion:* The auricular pillow method of aural hematoma management could be a better approach to the management of aural hematoma which is still a challenge in most clinical setting.

Key words: Aural Hematoma • Pillow Compression

INTRODUCTION

An aural hematoma is a collection of blood or serum within the cartilage plate of the pinna which presents as fluctuant, fluid-filled swelling(s) on the concave surface of one or both pinna [1]. It is the most common physical injury of the pinna with irritation from fly bite, otodectic mange and otitis as inciting causes [2]. Aural hematoma ranked eighth among the most common veterinary surgical procedures in North America [3] and the fifth commonest surgical conditions in Veterinary practice in South West, Nigeria [4].

The etio-pathogenesis of the condition is linked with vigorous head shaking or ear scratching caused by pain or irritation from trauma, otitis externa [1,5-8], or neoplasia and sometimes without evidence of ear disease [9]. This event results in the rupture of the branches of the caudal auricular arteries that penetrate the cartilage, or fracture of the auricular cartilage; causing a blood filled pinna [2]. Often, the bleeding within the cartilage continues until pressure within the hematoma cavity equals the pressure of the feeder arteries. Further head

shaking or scratching may increase the hematoma causing more separation of the cartilage [2]. As hematoma increase in size, the cushioning effects of the hematoma dissipate the shearing forces applied by the shaking and scratching. Delay in treatment leads to hematoma maturation and with fibrinolysis forms a sanguineous seroma. With chronicity, granulation tissues form on the cartilage walls of the hematoma [2] and without treatment, fibrosis and contraction thickens and deform the ear (cauliflower contracture) [10].

Several methods have been designed for aural hematoma management with therapeutic objectives focused at: identifying and treating the source of irritation, incision and establishment of drainage, maintenance of tissue apposition and prevention of reoccurrence. The *Marshall-Putney technique*, reported by Joyce [11], describes a method where an incision is made on the lateral surface of the pinna and the auricular cartilage to drain the hematoma. Buttons are then used to spread the pressure using through and through mattress sutures. Wilson [12] described a method in which a needle is used to aspirate the aural hematoma fluid,

followed by flushing of the cavity with saline and placement of a through and through penrose drain and attached at each end with non-absorbable sutures. An alternative method [12, 13] is with the use of a teat cannula which is inserted at the distal end of the pinna the drain is often left *in situ* for 3 weeks. The outcome using this method was reported to be good in 40 out of 47 cases. Reported complication was related to the patient removing the tube and poor cosmetic results. Kagan [14] also reported aural hematoma treatment in nine cases with an indwelling drain and concurrent compression of the ear by bandaging the ear to the head for 10–14 days. Fossum *et al.* [1] reported a treatment method in which following a full length incision of the hematoma, several simple interrupted sutures are placed through the concave surface of the pinna and the underlying cartilage parallel to the line of incision and the major vessels to obliterate the dead space. A light protective bandage is placed over the ear and the ear is supported over the head. Bandage and sutures are removed in 10-14 days.

Despite various surgical management methods employed in the treatment of this condition, a significant number recur with further cartilage scarification and worsen postoperative cosmetic outcome [11, 15]. These undesirable outcomes suggest a need for research in the management methods for aural hematoma. In this paper, a simple management

method which offered an acceptable cosmetic outcome is described. The dearth of information in literature on this method, coupled with comparative advantages of this method over other widely reported methods informed this report.

MATERIALS AND METHODS

Materials: Pebbles of varying sizes, cotton wool, a roll of adhesive tape, cut gauze sponges.

Methodology: Following premedication with intramuscular injection of 0.1% atropine sulphate (0.04 mg/kg), 3% pentazocine (2.0mg/kg) and sedation with 2% xylazine (2mg/kg) and aseptic preparation of the pinna (Figure 1a), a full length curvilinear incision is made on the concave side of the pinna over the hematoma (figure 1b). The hematoma content was evacuated, cavity flushed with normal saline and examined for cartilage damage (figure 1b). A sterile pebble of $\frac{1}{4}$ relative to the size of the hematoma is selected and padded with cotton wool and further with gauze bandage to serve as auricular pillow. The pinna was packed with the pillow support at the convex side and supported over the head with an adhesive tape (Figure 1c). The incision was covered with a non-adherent compression bandage for wound fluid absorption and strapped in place with adhesive tape

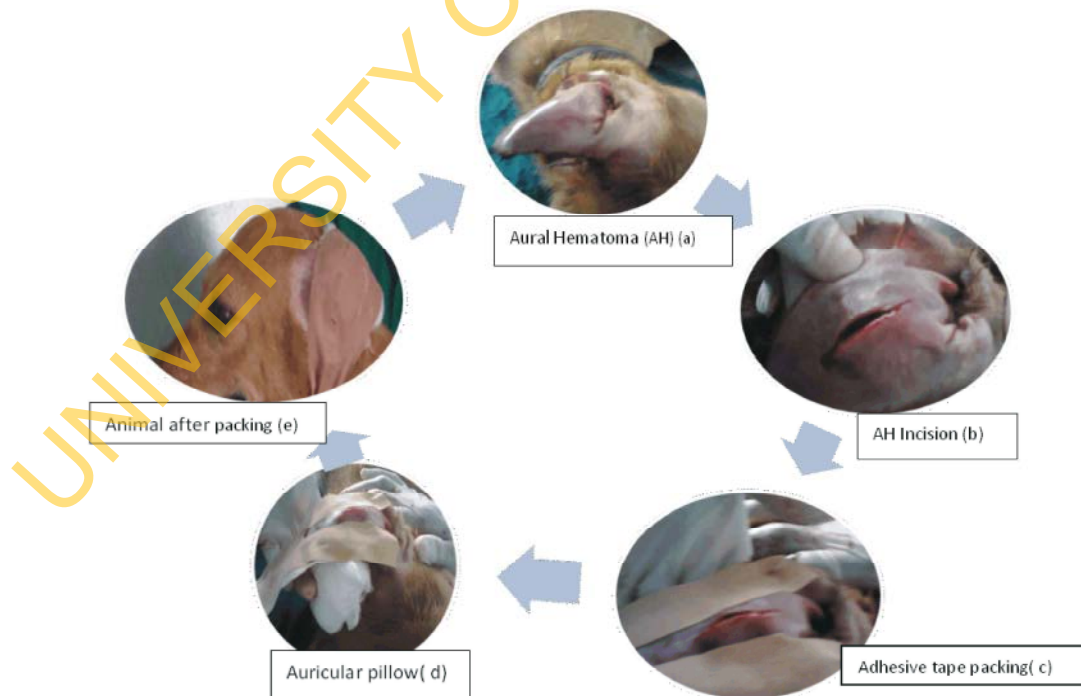


Fig. 1: Management of aural hematoma with auricular pillow method

(Figure 1d, 1e). The bandage was changed daily within the first three days post surgery during which wound and drainage effectiveness was assessed and the packing was removed between 14 and 28 days.

Comparison with Other Conventional Methods: The pillow method was compared with the suture and drains methods on the basis of materials for procedure, anesthetic requirement, postoperative analgesia, expertise involved, time involved, cost, chances of recurrence and cosmetic outcome.

RESULT

With early presentation and proper treatment of the inciting causes, the authors had an impressive and acceptable outcome in 100 % of cases. The effectiveness was assessed by evaluating the following:

Drainage: Drainage was effective. The un-sutured full length incision enabled unhindered flow of wound exudate. The dorsolateral pressure from the adhesive tape strap also enhanced evacuation of wound fluid (Figure 1c).

Compression: The auricular pillow provided a ventro-dorsal pressure which was countered by a corresponding gravitational force and dorso-lateral force from the adhesive tape strap thus obliterating the dead space (Figure 1c, 1d).

Cost Implications: The pillow method requires less surgical materials, drugs, time and expertise compared with the other conventional methods. (Table 1).

Cosmetic Outcome: The pillow method have better cosmetic outcome compared with the other conventional methods (Table 1, Figures 2).

Table 1: Comparison of the pillow method with other conventional aural hematoma management methods.

	<i>Pillow method</i>	<i>Suture method (Fossum et al., 2007)</i>	<i>Cannula/Drains method (Wilson, 1983)</i>
<i>Materials for procedure</i>	<i>Cotton wool, pebble, adhesive tape, bandage</i>	<i>Nylon sutures, cotton wool, adhesive tape, bandage.</i>	<i>Teat cannula/ penrose drains, cotton wool, adhesive tape, bandage.</i>
<i>Anesthesia</i>	<i>Mild sedation/analgesia</i>	<i>General anesthesia</i>	<i>Deep sedation or general anesthesia</i>
<i>Postoperative analgesia</i>	<i>Not necessary: operative analgesia sufficient for post operative pain.</i>	<i>Strong opioid due to pain from skin and cartilage sutures</i>	<i>Strong opioid due to pain from drain tacking sutures.</i>
<i>Expertise involve</i>	<i>low</i>	<i>highest</i>	<i>lower</i>
<i>Time involved</i>	<i>less</i>	<i>most</i>	<i>more</i>
<i>Inferred cost</i>	<i>less</i>	<i>Most</i>	<i>more</i>
<i>Chances of recurrence</i>	<i>Not yet recorded</i>	<i>Mostly due to suture granuloma and lacerations</i>	<i>less</i>
<i>Cosmetic outcome</i>	<i>Interestingly wonderful</i>	<i>Good if there is no poor suture placement and drainage and recurrence (Cechner, 1990)</i>	<i>poor</i>

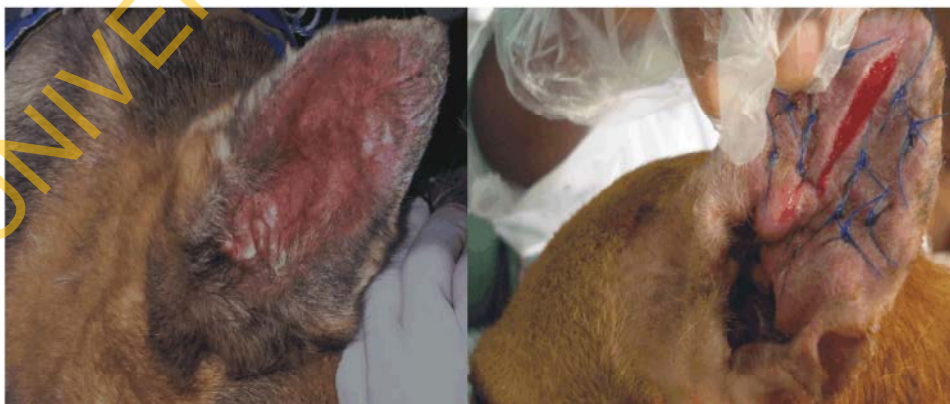

Fig. 2A: A dog treated with pillow compression method by the authors. Observe healing with ears erect without support.

B: Dog treated with suture method

Recurrence: The authors have not recorded recurrence after the treatment of the inciting cause. The suture method (Figure 3) has inherent deficiencies such as suture induced lacerations and granulomas that encourages recurrence.

Comparison of Pillow Method with Other Conventional Methods: This was as shown in Table 1.

DISCUSSION

Several methods have been reported in literature for the management of aural hematoma [7, 12, 14, 16-19]. The disparity in management methods depend on the management objectives of the clinician/surgeon. The teat cannula and drains methods [13,14] were suggested for aural hematoma management with minimal fibrin deposits [1]. The amount of fibrin deposits in a hematoma, however, cannot be clinically evaluated without exposure of the hematoma cavity. This deficiency coupled with lack of compression of dead space and continual trauma to the auricular cartilage from head shaking often makes this method non-satisfactory and prone to poor cosmetic outcome [14]. A full length hematoma incision with drainage and suture placement has been reported by some authors [1]. The method was used to achieve drainage and compression objectives and has been used by the authors too (Figure 2B). The deficiencies in the method include: the need for general anesthesia and a strong postoperative analgesia due to the associated pain. It also requires placement of several sutures on the fractured and traumatized auricular cartilage to occlude dead space. Besides, following healing, the sutures cut through the auricular skin resulting in lacerations, further irritation and hematoma recurrence (Authors' personal observations). Also, recurrence and permanent scarring may result from poor drainage, poor suture placement, or inadequate suture numbers [7].

The method presented in this paper is a modification of surgical incision, drainage and compression bandage method [18]. The pillow method satisfies the three basic principal objectives (Drainage, compression and auricular cartilage healing) emphasized in aural hematoma management [12]. The full length incision enhances complete evacuation of hematoma contents and evaluation of the auricular cartilage for extent of damage. Drainage is further enhanced by non-closure of the incision and a dorsal-lateral force produced by the non-adherent compression bandage and adhesive tape strips placed over the pinna and anchored to the head.

Compression is further produced by the dorsal-ventral gravitational force and a counteracting ventro-dorsal reaction force from the pillow in accordance with Newton's third law of motion [20]. The combination of drainage, compression and packing produces auricular cartilage quiescence and rest from trauma induced violent headshaking leading to cartilage healing and restoration of pinna morphology following the procedure. Although the use of a pebble as the pillow hard core may be unacceptable in some modern setting, the pebble may be replaced with a more suitable material to satisfy the principle and achieve the objective of placement. It is noteworthy however, that pebbles are universally available materials which could be obtained at no cost for the procedure especially in a poor resource setting. The auricular pillow method with its characteristic better drainage, compression, less cost of materials and minimal expertise, coupled with appreciable cosmetic outcome could be a better approach to the management of aural hematoma which is still a challenge in most clinical settings.

REFERENCES

1. Fossum, T.W., S.H. Cheryl, A.L. Johnson, K.S. Schulz, H.B. Seim, M.D. Willard, A. Bahr and G.L. Carroll, 2007. Aural hematomas and Traumatic lesions of the pinna. In Textbook of Small Animal Surgery 3rd Edition : Eds.,Theresa Welch Fossum: Elsevier science, Morsby Inc Publishers, pp: 307-312.
2. Henderson, R.A. and R. Homes, 2002. Pinna. In Textbook of small animal surgery 3rd edition. Eds., Slatter Douglas: Saunders W.B. Publishers, 2: 1737-1740.
3. Johnson, A.L., C.L. Greenfield, L. Klippert, L.L. Hungerford, J.A. Farmer and A. Siegel, 1993. Frequency of Procedure and Proficiency expected of new Veterinary School Graduates with regard to Small Animal Surgical Procedures in private practice. Journal of American Veterinary Medical Association, 202: 1068-1070.
4. Eyarefe, O.D., T.O. Alonge and E.O. Fayemi, 2011. The incidence of intestinal obstructive diseases in selected veterinary clinics and hospitals in South Western Nigeria. Nigerian Veterinary Journal, 32(1): 36-39.
5. Dubielzig, R.R., J.W. Wilson and A.A Seireg, 1984. Pathogenesis of Canine Aural Hematoma. Journal of American Veterinary Medical Association, 185: 873-875.

6. Fraser, G., W.W. Gregor, C.P. Mackenzie, J.S.A. Spreull and A.R. Withers, 1970. Canine ear disease. *Journal of Small Animal Practice*, 10: 725-754.
7. Cechner, P.E., 1990. Suture technique for repair of aural hematoma. In *Current Techniques in Small Animal Surgery*. 3rd Edition; Eds., M. Joseph Bojrab: Lippincott Williams & Wilkins publishers, pp: 133-135.
8. Mikawa, K., T. Itoh, K. Ishikawa, K. Kushima, K. Uchida and H. Shii, 2005. Epidemiological and Etiological Studies on 59 Aural Hematomas of 49 Dogs. *Japanese Journal of Veterinary Anesthesia & Surgery*, 36(4): 87-91.
9. Joyce, J.A., 1994. Treatment of canine aural hematoma using an indwelling drain and corticosteroids. *Journal of Small Animal Practice*, 35: 341-344.
10. Eger, C.E. and P. Lindsey, 1997. Effects of otitis on hearing in Dog characterized by brain stem auditory evoked response testing. *Journal of Small Animal Practice*, 38: 380.
11. Joyce, J.A., 2000. Canine Aural hematoma. *Waltham focus*, 10(4): 4-9.
12. Wilson, J.W., 1983. Treatment of auricular hematoma, using a Teat-tube. *Journal of American Veterinary Medical Association*, 182: 1081-1083.
13. Swain, S.F. and D.M. Bradley, 1996. Evaluation of closed-suction drainage for treating auricular hematoma. *Journal of American Veterinary Medical Association*, 32: 36-43.
14. Kagan, K.G., 1983. Treatment of canine aural hematoma with an indwelling drain. *Journal of American Veterinary Medical Association*, 183: 972-974.
15. Kuwahara, J., 1986. Canine and feline aural hematoma: clinical, experimental and clinicopathologic observations. *American Journal of Veterinary Research*, 47: 2300-2308.
16. Swaim, S.F. and D.M. Bradley, 1996. Evaluation of closed-suction drainage for treating auricular hematomas. *Journal of the American Animal Hospital Association*, 32(1): 36-43.
17. Dye, T.L., H.D. Teague, D.A. Oswald and S.D. Ferreira, 2002. Evaluation of a technique using the carbon dioxide laser for the treatment of aural hematoma. *Journal of American Animal Hospital Association*, 38(4): 385-390.
18. Bojrab, M.J. and G.M. Constantinescu, 1990. Sutureless technique for repair of aural hematoma. In *Current Techniques in Small Animal Surgery*. 3rd Edition; Eds., M. Joseph Bojrab: Lippincott Williams & Wilkins publishers, pp: 135-136.
19. Blattler, U., O. Harlin, R.G. Matterson and F. Rampelberg, 2007. Fibrin sealant as a treatment for canine aural haematoma: a case history. *Veterinary Journal*, 173(3): 697-700.
20. Shipman, J.T., J.D. Wilson, A. Todd and C.A. Higgins, 2012. Newton third law of motion. In *An Introduction to Physical Science* 13th Edition. Eds., James T Shipman: Mary Finch publisher, pp: 59-72.