



RESEARCH NOTE

Pattern of triple negative epithelial ovarian cancer in indigenous African women [version 1; referees: 2 approved]

Mustapha Akanji Ajani¹, Ayodeji Akeem Salami¹, Olutosin Alaba Awolude²,
Abideen Olayiwola Oluwasola¹

¹Department of Pathology, University College Hospital, Ibadan, Nigeria
²Department of Obstetrics and Gynaecology, University College Hospital, Ibadan, Nigeria

v1 First published: 28 Sep 2016, 5:2415 (doi: [10.12688/f1000research.9632.1](https://doi.org/10.12688/f1000research.9632.1))
Latest published: 28 Sep 2016, 5:2415 (doi: [10.12688/f1000research.9632.1](https://doi.org/10.12688/f1000research.9632.1))

Abstract

Background: Triple negative epithelial ovarian cancer (TNEOC) refers to ovarian carcinomas that do not express estrogen receptor (ER), progesterone receptor (PR) and human epidermal growth factor receptor- type 2 (HER-2/neu). The aim of this study is to determine the pattern of triple negative epithelial ovarian cancer in indigenous African women.

Methods: We performed a retrospective review of ER, PR and HER-2/neu expression in 90 Nigerian patients with histologically diagnosed epithelial ovarian cancer. Lack of expression of ER, PR and HER2/neu antigens was used to determine carcinomas that are among the TNEOC. We also compared the clinicopathological parameters (age, International Federation of Gynaecology and Obstetrics (FIGO) stage, grade and histological subtype) in patients with TNEOC and non- TNEOC .

Results: Thirty-eight (42.2%) of the 90 tumours diagnosed as EOC were negative for ER, PR and HER2/neu expression. There was no significant association between TNEOC with other parameters such as age, FIGO stage and histological grade. Sixteen (66.7%) of the 24 mucinous carcinomas were triple negative, while only 21 (33.3%) of the 63 serous carcinomas were triple-negative and one (50%) of the two endometrioid carcinomas was triple negative. There was a significant association between triple-negative tumours and histological subtypes of EOC (p = 0.034).

Conclusions: A subtype of epithelial ovarian cancer that is negative for ER, PR and HER-2/neu has been discovered in indigenous African women. TNEOC expression is high and is comparable to the triple negative breast cancer subtype seen in people of African ancestry. Future study of TNEOC in a large sample size should be considered.

Open Peer Review

Referee Status:

	Invited Referees	
	1	2
version 1 published 28 Sep 2016	<input checked="" type="checkbox"/> report	<input checked="" type="checkbox"/> report
<hr/>		
1 Akinwumi Komolafe , Obafemi Awolowo University Nigeria		
2 Saad Aliyu Ahmed , Ahmadu Bello University Teaching Hospital (ABUTH) Nigeria		
<hr/>		
Discuss this article		
Comments (0)		

Corresponding author: Mustapha Akanji Ajani (ajanimustapha@yahoo.com)

How to cite this article: Ajani MA, Salami AA, Awolude OA and Oluwasola AO. **Pattern of triple negative epithelial ovarian cancer in indigenous African women [version 1; referees: 2 approved]** *F1000Research* 2016, 5:2415 (doi: [10.12688/f1000research.9632.1](https://doi.org/10.12688/f1000research.9632.1))

Copyright: © 2016 Ajani MA *et al.* This is an open access article distributed under the terms of the [Creative Commons Attribution Licence](#), which permits unrestricted use, distribution, and reproduction in any medium, provided the original work is properly cited. Data associated with the article are available under the terms of the [Creative Commons Zero "No rights reserved" data waiver](#) (CC0 1.0 Public domain dedication).

Grant information: The authors declared that no grants were involved in supporting this work.

Competing interests: No competing interests were disclosed.

First published: 28 Sep 2016, 5:2415 (doi: [10.12688/f1000research.9632.1](https://doi.org/10.12688/f1000research.9632.1))

UNIVERSITY OF IBADAN LIBRARY

Introduction

Epithelial ovarian cancer (EOC) remains one of the leading causes of death in gynaecological malignancies in developed countries¹⁻⁴. The initial symptoms of ovarian cancer are often ambiguous, therefore it goes undiagnosed until after the disease is far advanced and has spread throughout the abdomen or to distant organs^{5,6}.

Steroid hormone receptors expression in epithelial ovarian cancers have been proposed to have therapeutic and prognostic relevance, as is the case in breast cancers⁷. The determination of tumour characteristics such as age, International Federation of Gynaecology and Obstetrics (FIGO) stage, grade and histological subtypes has been associated with clinical behaviour and impact on treatment and prognosis but have been found to be limited⁸. Among the biological parameters proposed as possible prognostic factors in ovarian cancer, estrogen receptor (ER), progesterone receptor (PR) and human epidermal growth factor receptor- type 2 (HER-2/neu) have been tested as potential biomarkers that guide individualized treatment of the cancer^{5,6,9}. Epithelial ovarian carcinoma results from repeated ovulations, where the cumulative effects of each minor trauma on the ovarian epithelium can lead to malignant transformation¹⁰. PR has been observed to predict better prognosis because of its protection against ovarian carcinoma development^{11,12}. On the other hand, overexpression of ER has been found to be associated with poor prognosis due to its contribution to initiation and/or promotion of ovarian carcinogenesis^{10,13}. The HER-2/neu has been shown to be over-expressed in approximately 20–30% of EOC with associated poor prognosis¹⁴⁻¹⁶.

Triple negative epithelial ovarian cancer (TNEOC) cases have been found to be more aggressive and display a worse prognosis than non-TNEOC cases¹⁷. This was similarly observed in the studies of triple negative breast cancer^{18,19}.

This study was designed to determine the pattern of TNEOC among indigenous African women and correlate it with clinicopathological parameters.

Methods

Patient selection

We performed a retrospective review of ER, PR and HER-2/neu expression in 90 patients with histologically diagnosed epithelial ovarian cancer seen at the University College Hospital, Ibadan, Nigeria between January 2006 and December 2012. Non-epithelial primary ovarian cancers and metastatic cancers in the ovary were not included in this study. The demographic data and clinical history of these cases were obtained from the case notes, surgical daybooks, surgical pathology request forms, post-mortem records and Cancer Registry data. Formalin-fixed paraffin-embedded tissue blocks of histologically diagnosed solid EOC between January 2006 and December 2012 were retrieved and used for the study. The microscopic grading (three-grade system) of Shimizu and Silverberg was used, which assesses architectural pattern, nuclear pleomorphism and mitotic activity²⁰. All histological classification of the EOC was based on the 2013 World Health Organisation (WHO) classification of ovarian tumours²¹. The FIGO

staging of the cases used for this study was extracted from the case notes of the patients.

Ethics

The ethical clearance for this study was obtained from the Joint University of Ibadan/University College Hospital Ethical Review Committee (approval number UI/EC/13/0050) according to the Declaration of Helsinki.

Immunohistochemistry

The immunostaining procedure for HER-2/neu was carried out in accordance with the previously published article²². For the immunostaining procedure, three sections each for ER, PR and HER-2/neu at 5µm were cut from each of the paraffin-embedded tissue blocks after deparaffinization in xylene (two aliquots for five minutes each with the xylene covering the slide entirely). The sections were then rehydrated in graded alcohol concentrations (two aliquots each of 100% and 95% each and a single aliquot of 70%) in 250ml couplin jars. The antibodies used were monoclonal mouse anti-human ERα (Dako USA; clone ID5) and monoclonal mouse anti-human PR (Dako USA; clone PgR636) which identify the ER and PR nuclear protein antigens. The primary antibody used for HER-2/neu antigen was polyclonal rabbit anti-human C-erbB-2 (MBO/TEG, Dako USA, 1:800). The tissue sections were immersed in EDTA buffer (pH 9.0) for ER, citrate buffer (pH 6.0) for PR and in 1M Tris buffer (pH 9.0) for HER-2/neu. These slides were then incubated at room temperature for 20 minutes with primary monoclonal antibodies against ER (Dako USA, clone ID5; 1:50), PR (Dako USA, clone PgR636; 1:50) and polyclonal rabbit anti-human C-erbB-2 (MBO/TEG, Dako USA, 1:800) followed by incubation in biotin-labelled secondary antibodies, polyclonal goat anti-mouse antibody for both ER and PR, (Dako USA, REF: K0675, LOT: 10081219) and polyclonal goat anti-rabbit antibody for HER-2/neu, (kitR, K5001, Dako Denmark) for 20 minutes and streptavidin-peroxidase complex (Dako USA, REF: K0675, LOT: 10084687) for another twenty minutes. The antigen-antibody complex was precipitated with di-aminobenzidine (DAB) for light microscopy with DAB substrate and DAB chromogen in the ratio of 1ml to 1 drop respectively. This was thereafter counterstained in Mayer's haematoxylin (Dako USA). Dehydration of the sections was performed in ascending grades of alcohol and cleared in xylene. The slides were coverslipped with DPX mountant. Known cases of breast cancer with positive reactions for ER, PR and HER-2/neu were used as a positive control. Negative controls were cases of tumour sections that were pretreated in Tris but without primary antibody immunostaining. All slides were reviewed independently by the three of the authors and cases with discordant scores were re-evaluated to have a consensus score. Grading of nuclear ER and PR staining was performed using an immunoreactive H-scoring system {none= 0 (negative); 1–25%=1+ (weak); 26–50%=2+ (moderate); >50%=3+(strong)}¹¹. HER-2/neu membrane staining was graded in according to the Hercep Test protocol system as 0, 1+, 2+ or 3+. Samples scored as 0 or 1+ were considered negative for HER-2/neu overexpression, 2+ was weakly positive and 3+ was strongly positive^{22,23}. Photomicrographs of the specimens were taken using Olympus digital camera, DP 21 at 400X magnification (Figure 1).

Statistical analysis

The data obtained were subjected to statistical analysis using Statistical Package for Social Sciences (SPSS) version 20. Statistical analysis was used to evaluate statistical associations between TNEOC and clinicopathological parameters i.e. age, FIGO stage grade, and histological subtypes. Continuous variables were compared using the student's T test and categorical variables were compared using the chi-square test, with the level of significance set at $p < 0.05$.

Results

Dataset 1. Raw data for 'Pattern of triple negative epithelial ovarian cancer in indigenous African women'

<http://dx.doi.org/10.5256/f1000research.9632.d136777>

Thirty-eight (42.2%) of the 90 epithelial ovarian cancers (EOC) were negative for ER, PR and HER-2/neu expression (Figure 1). There was no significant association between triple-negative EOC and age ($p = 0.218$), FIGO stage ($p = 0.425$) and histological grade ($p = 0.269$). There were more TNEOC cases seen in patients older than 40 years than those below 40 years of age. Of 38 cases of TNEOC, 21 (55.3%) were found in the early stage (FIGO stage I and II) of epithelial ovarian cancer and 17 (44.7%) were at the advanced stage.

However, sixteen (66.7%) of the 24 mucinous carcinomas were triple-negative, while only 21 (33.3%) of the 63 serous carcinomas were triple-negative and one (50%) of the two endometrioid carcinomas was triple-negative (Table 1). There was therefore a significant association between triple-negative tumours and histological subtypes of EOC ($p = 0.034$).

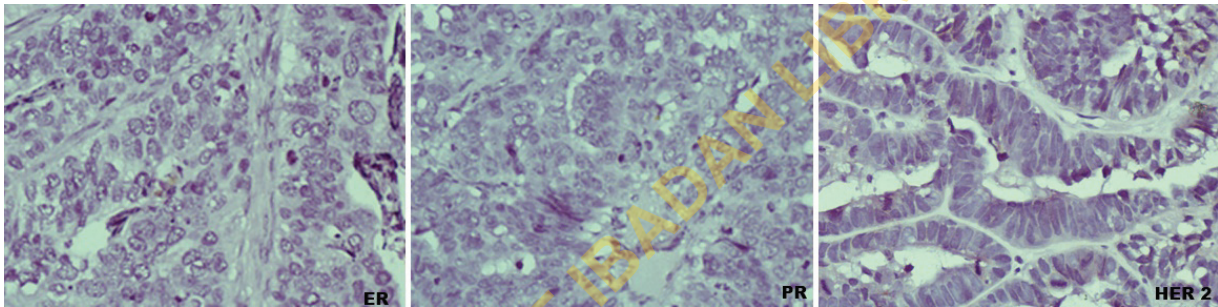


Figure 1. Photomicrographs showing ER (left), PR (middle) and HER-2/neu (right) negative expression (TNEOC) (immunostaining, 400X).

Table 1. Correlation between triple negative epithelial ovarian cancer and clinicopathological parameters.

	TNEOC	Non-TNEOC	Total	P value
Age				
<40	9	4	13	
>40	29	48	77	0.218
FIGO Stage				
I-II	21	22	43	
III-IV	17	30	47	0.425
Histological grade				
I	10	9	19	
II	16	18	34	
III	12	25	37	
Histological subtypes				
Serous Carcinoma	21	42	63	
Mucinous Carcinoma	16	8	24	
Endometrioid Carcinoma	1	1	2	
Malignant Brenner tumour	0	1	1	0.034
Total	38	52	90	

Discussion

A subgroup of epithelial ovarian cancer that is negative for ER, PR and HER-2/neu expression has been identified among indigenous African women. This subgroup is known as triple negative epithelial ovarian cancer (TNEOC). According to ER, PR, and HER-2/neu expressions, a breast cancer subtype known as triple negative breast cancer (TNBC) has been identified²⁴.

In our study, triple negative tumours accounted for 42.2% of EOC. This value contrasts with the results of other studies^{17,25} and compares with the results of previous study²⁶. A significant percentage (66.7%) of mucinous carcinoma were negative for ER, PR and HER-2/neu and this was statistically significant ($p=0.034$). This finding contrasts what was found from previous studies where there was no significant association between the TNEOC and histological subtypes^{17,25,26}. No significant association was also found between the TNEOC and histological grade unlike what was observed by Liu *et al.*¹⁷ and de Toledo *et al.*²⁶ where TNEOC was significantly correlated with histological grade. There was no significant association between TNEOC and age and FIGO stage compared to the findings of other studies^{17,25,26}.

Our findings were comparable with what was found by Huo *et al.* in the population differences in breast cancer where triple negativity was predominant (27%)¹⁹. In view of the fact that triple-negative breast cancers are more often seen in black Africans and African-Americans and are associated with a poorer prognosis than non-triple-negative breast cancers, further studies of TNEOC in different environments are required.

Conclusions

A subtype of epithelial ovarian cancer that is negative for ER, PR and HER-2/neu has been discovered in Nigeria. Its (TNEOC)

expression is high and is comparable to the triple negative breast cancer subtype seen in people of African ancestry. Future study of TNEOC in a large sample size should be considered.

Data availability

F1000Research: Dataset 1. Raw data for 'Pattern of triple negative epithelial ovarian cancer in indigenous African women', [10.5256/f1000research.9632.d136777](https://doi.org/10.5256/f1000research.9632.d136777)²⁷

Author contributions

MAA conceived and designed the study. MAA, AAS and AOO carried out the research. MAA and AOO prepared the first draft of the manuscript. All authors contributed to the experimental design and preparation of the manuscript. All authors were involved in the revision of the draft manuscript and have agreed to the final content.

Competing interests

No competing interests were disclosed.

Grant information

The author(s) declared that no grants were involved in supporting this work.

Acknowledgements

Special thanks to Mr S Ajagboye and Mr SP Otegbade of the Department of Pathology, University of Ibadan and University College Hospital respectively for the technical assistance they rendered with the slides used for this study and Mr Abayomi Odetunde of Institute for Advanced Medical Research and Training, College of Medicine, University of Ibadan for carrying out the immunohistochemical staining on the cases.

References

- Hunn J, Rodriguez GC: **Ovarian cancer: etiology, risk factors, and epidemiology.** *Clin Obstet Gynaecol.* 2012; **55**(1): 3–23.
[PubMed Abstract](#) | [Publisher Full Text](#)
- Jemal A, Bray F, Center MM, *et al.*: **Global cancer statistics.** *CA Cancer J Clin.* 2011; **61**(2): 69–90.
[PubMed Abstract](#) | [Publisher Full Text](#)
- Barrena Medel NI, Wright JD, Herzog TJ: **Targeted therapies in epithelial ovarian cancer.** *J Oncol.* 2010; **2010**: 314326.
[PubMed Abstract](#) | [Publisher Full Text](#) | [Free Full Text](#)
- Swamy GG, Satyanarayana N: **Clinicopathological analysis of ovarian tumors—a study on five years samples.** *Nepal Med Coll J.* 2010; **12**(4): 221–223.
[PubMed Abstract](#)
- Dinh P, Harnett P, Piccart-Gebhart MJ, *et al.*: **New therapies for ovarian cancer: cytotoxics and molecularly targeted agents.** *Crit Rev Oncol Hematol.* 2008; **67**(2): 103–12.
[PubMed Abstract](#) | [Publisher Full Text](#)
- Yap TA, Carden CP, Kaye SB: **Beyond chemotherapy: targeted therapies in ovarian cancer.** *Nat Rev Cancer.* 2009; **14**(3): 167–81.
[PubMed Abstract](#) | [Publisher Full Text](#)
- Scambia G, Ferrandina G, D'Agostino G, *et al.*: **Oestrogen and progesterone receptors in ovarian carcinoma.** *Endocrine Rel Cancer.* 1998; **5**: 293–301.
[Publisher Full Text](#)
- de Toledo MC, Barreta A: **The Role of Steroid Receptors and HER2 in Ovarian Cancer.** *J Carcinog Mutagen.* 2014; **5**: 1.
[Publisher Full Text](#)
- Tuefferd M, Couturier J, Penault-Llorca F, *et al.*: **HER2 status in ovarian carcinomas: a multicenter GINECO study of 320 patients.** *PLoS One.* 2007; **2**(11): e1138.
[PubMed Abstract](#) | [Publisher Full Text](#) | [Free Full Text](#)
- Fathalla MF: **Incessant ovulation—a factor in ovarian neoplasia?** *Lancet.* 1971; **2**(7716): 163.
[PubMed Abstract](#) | [Publisher Full Text](#)
- Ayadi L, Chaabouni S, Khabir A, *et al.*: **Correlation between immunohistochemical biomarkers expression and prognosis of ovarian carcinomas in Tunisian patients.** *World J Oncol.* 2010; **1**(3): 118–128.
[Publisher Full Text](#)
- Lee P, Rosen DG, Zhu C, *et al.*: **Expression of progesterone receptor is a favorable prognostic marker in ovarian cancer.** *Gynaecol Oncol.* 2005; **96**(3): 671–677.
[PubMed Abstract](#) | [Publisher Full Text](#)
- Zhao D, Zhang F, Zhang W, *et al.*: **Prognostic role of hormone receptors in ovarian cancer: a systematic review and meta-analysis.** *Int J Gynecol Cancer.*

- 2013; **23**(1): 25–33.
[PubMed Abstract](#) | [Publisher Full Text](#)
14. Hellström I, Goodman G, Pullman J, *et al.*: **Overexpression of HER-2 in ovarian carcinomas.** *Cancer Res.* 2001; **61**(6): 2420–2423.
[PubMed Abstract](#)
 15. Cirisano FD, Karlan BY: **The role of the HER-2/neu oncogene in gynecologic cancers.** *J Soc Gynecol Investig.* 1996; **3**(3): 99–105.
[PubMed Abstract](#)
 16. Yu D, Wolf JK, Scanlon M, *et al.*: **Enhanced c-erbB-2/neu expression in human ovarian cancer cells correlates with more severe malignancy that can be suppressed by E1A.** *Cancer Res.* 1993; **53**(4): 891–898.
[PubMed Abstract](#)
 17. Liu N, Wang X, Sheng X: **The clinicopathological characteristics of 'triple-negative' epithelial ovarian cancer.** *J Clin Pathol.* 2010; **63**(3): 240–243.
[PubMed Abstract](#) | [Publisher Full Text](#)
 18. Chacón RD, Costanzo MV: **Triple-negative breast cancer.** *Breast Cancer Res.* 2010; **12**(Suppl 2): S3.
[PubMed Abstract](#) | [Publisher Full Text](#) | [Free Full Text](#)
 19. Huo D, Ikpatt F, Khramtsov A, *et al.*: **Population differences in breast cancer: survey in indigenous African women reveals over-representation of triple-negative breast cancer.** *J Clin Oncol.* 2009; **27**(27): 4515–4521.
[PubMed Abstract](#) | [Publisher Full Text](#) | [Free Full Text](#)
 20. Shimizu Y, Kamoi S, Amada S, *et al.*: **Toward the development of a universal grading system for ovarian epithelial carcinoma. I. Prognostic significance of histopathologic features--problems involved in the architectural grading system.** *Gynecol Oncol.* 1998; **70**(1): 2–12.
[PubMed Abstract](#) | [Publisher Full Text](#)
 21. Tassovoli FA, Devilee P: **Pathology and Genetics. Tumours of the Breast and Female Genital Organs.** Lyon, IARC Press. 2003; 114.
[Reference Source](#)
 22. Ajani MA, Salami A, Awolude OA, *et al.*: **The expression status of human epidermal growth factor receptor 2 in epithelial ovarian cancer in Ibadan, Nigeria.** *South Afr J Gynaecol Oncol.* 2016; **8**(1): 9–13.
[Publisher Full Text](#)
 23. Wolff AC, Hammond ME, Schwartz JN, *et al.*: **American Society of Clinical Oncology/College of American Pathologists guideline recommendations for human epidermal growth factor receptor 2 testing in breast cancer.** *J Clin Oncol.* 2007; **25**(1): 118–145.
[PubMed Abstract](#) | [Publisher Full Text](#)
 24. Reis-Filho JS, Tutt AN: **Triple negative tumours: a critical review.** *Histopathology.* 2008; **52**(1): 108–118.
[PubMed Abstract](#) | [Publisher Full Text](#)
 25. Demir L, Yigit S, Sadullahoglu C, *et al.*: **Hormone Receptor, HER2/NEU and EGFR expression in ovarian carcinoma--is here a prognostic phenotype?** *Asian Pac J Cancer Prev.* 2014; **15**(22): 9739–9745.
[PubMed Abstract](#) | [Publisher Full Text](#)
 26. de Toledo MC, Sariana LO, Salluma LF, *et al.*: **Analysis of the contribution of immunologically-detectable HER2, steroid receptors and of the "triple-negative" tumor status to disease-free and overall survival of women with epithelial ovarian cancer.** *Acta Histochemica.* 2014; **116**(3): 440–447.
[PubMed Abstract](#) | [Publisher Full Text](#)
 27. Ajani MA, Salami AA, Awolude OA, *et al.*: **Dataset 1 in: Pattern of triple negative epithelial ovarian cancer in indigenous African women.** *F1000Research.* 2016.
[Data Source](#)

UNIVERSITY OF IBADAN LIBRARY

Open Peer Review

Current Referee Status:



Version 1

Referee Report 13 October 2016

doi:10.5256/f1000research.10379.r16697



Saad Aliyu Ahmed

Department of Pathology, Ahmadu Bello University Teaching Hospital (ABUTH), Zaria, Nigeria

1. This is an interesting manuscript, well conceived and has addressed the objective of the research.
2. The methodology is simple and reproducible.
3. Result was clearly outlined and discussion was adequate.
4. Conclusion is apt.

This research finding will add to the few literature on TNEOC in the population studied. It will serve as a baseline for future reference and interestingly the research has prognostic and therapeutic implications.

I have read this submission. I believe that I have an appropriate level of expertise to confirm that it is of an acceptable scientific standard.

Competing Interests: No competing interests were disclosed.

Referee Report 11 October 2016

doi:10.5256/f1000research.10379.r16923



Akinwumi Komolafe

Department of Morbid Anatomy and Forensic Medicine, Obafemi Awolowo University, Ilé-Ife, Nigeria

I have gone through the whole paper and these are my comments:

1. It is a well conceived and conducted research paper with the aims and objectives and rationale for the study well spelled out.
2. It addresses the peculiarities of the African race which is fundamental to adequate care.
3. The authors are very clear and consistent in the message that they aimed to convey and have passed this through.

4. All parts of the research work have fulfilled the guidelines for sound scientific work.
5. The discussion addresses crucial details.
6. The conclusion is a brilliant and excellent summation of the author's scientific work.

I have read this submission. I believe that I have an appropriate level of expertise to confirm that it is of an acceptable scientific standard.

Competing Interests: No competing interests were disclosed.

UNIVERSITY OF IBADAN LIBRARY