

ENDODONTIC TREATMENT OF UNUSUALLY LONG DISCOLORED MAXILLARY CENTRAL INCISOR: A CASE REPORT

I.M.F. Abiodun-Solanke, D.M. Ajayi and A.O. Abu

Department of Restorative Dentistry, College of Medicine, University College Hospital, Ibadan, Nigeria

Correspondence:

Dr. I.M.F. Abiodun-Solanke
Dept. of Restorative Dentistry,
College of Medicine,
University College Hospital,
Ibadan, Nigeria.
Tel: +234-802-375-4987
E-mail: abisolimf@yahoo.ca

ABSTRACT

Background: Success in root canal treatment is achieved after thorough biomechanical preparation followed by complete obturation of the canal system together with prompt and adequate restoration. Therefore, the endodontic therapy requires specific and complete knowledge of the internal and external anatomy, and its variation in presentation. Such treatment may be performed in root canal systems that do not comply with normal anatomic features described in standard textbooks. This article presents a case of endodontic treatment in an unusually long discolored maxillary central incisor.

Case Presentation: A 31 year-old male patient was referred to conservation clinic for endodontic treatment of discolored left maxillary central incisor with associated history of recurrent swelling. Root canal therapy was performed and patient was found to have an unusually long working length of 29mm. This was then followed by enucleation of apical cyst without apical resection.

Conclusion: Though the patient presents a maxillary central incisor with canal length in the upper limit of some reported cases, it is unusual in our environment.

Keywords: Endodontic, Maxillary central, Unusually long, Treatment

INTRODUCTION

A broad knowledge of both the external and internal anatomy of teeth is of great importance for adequate endodontic treatment¹. Human dentition presents a variety of anatomical and morphological variations. However, the reported incidences of such variations in the maxillary central incisors are very few. Maxillary central incisor has one root and one canal but recently a few cases of dual-rooted maxillary central incisor have been reported in literature¹⁻⁵. Maxillary central incisors vary in root length with reported average length of 22mm to 23.8mm⁶⁻⁸.

Weine⁹ in 1976 published a data for average tooth lengths in North Americans which were obtained from working lengths of his patients using the radiographic method. In an in-vitro study by Okpo and Akpata⁸ in 1986, the length of maxillary central incisor was reported to range from 20.0-28.0mm with a mean of 23.8mm. There is however a dearth of literature on length of maxillary central incisor among black Africans using clinical studies.

The following case report describes the endodontic management of a patient with an unusually long maxillary central incisor in our environment.

CASE PROFILE

A 31 year-old male was referred for the treatment of discoloured left maxillary central incisor. He noticed the discolouration of the tooth seven years before presentation, which could not be associated with any known cause. There was associated pain and swelling with pus discharge four years before presentation which subsided after medication. His medical history was unremarkable and non-contributory.

Clinical examination revealed a discoloured, mesio-labially rotated left maxillary central incisor.

Radiograph revealed a well circumscribed peri-apical radiolucency with sclerotic border in relation to left maxillary central incisor (Fig. 1). An assessment of periapical cyst was made and patient scheduled for root canal treatment followed by peri-radicular surgery for cyst enucleation.

The tooth was isolated with rubber dam. Access gained to the pulp chamber from the palatal surface a triangular shaped cavity with apex pointing to the cingulum and base towards the incial edge. Canal was located and the pulp was already necrotic. A 25 mm ISO size 25 K file (Premier Dental Products Co, Canada, PA.) was

placed in the root canal at full length without encountering any resistance, radiograph taken revealed that the file was short of the radiographic terminus by 4mm. Therefore, a size 31mm ISO size 25 Kfile was then placed in the root canal at 29mm using digital tactile sensation and the repeated working length radiograph showed that the file was at the radiographic

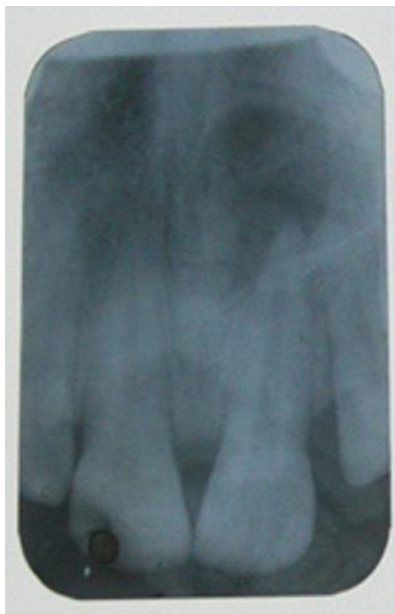

Fig 1: Pre-op periapical X-ray view

terminus (Fig. 2). Biomechanical preparation of the root canal was carried out with serial K files ranging from ISO size 25 to ISO size 50 (Premier Dental Products Co, Canada, PA.), using step back technique under continuous irrigation with 2.5% sodium hypochlorite solution (Reckitt Benckiser Ltd, Agbara, Nigeria). When preparation was completed, the canal

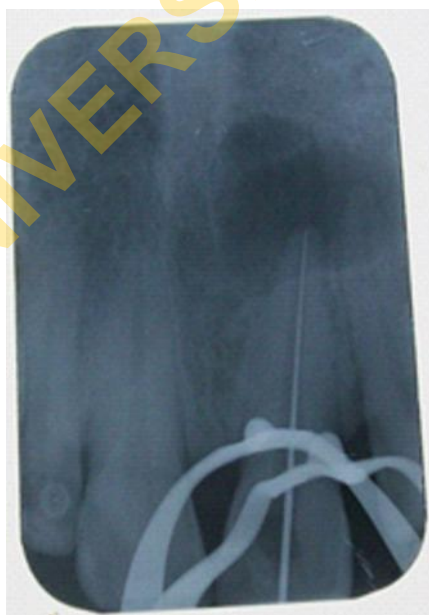

Fig 2: Working length determination

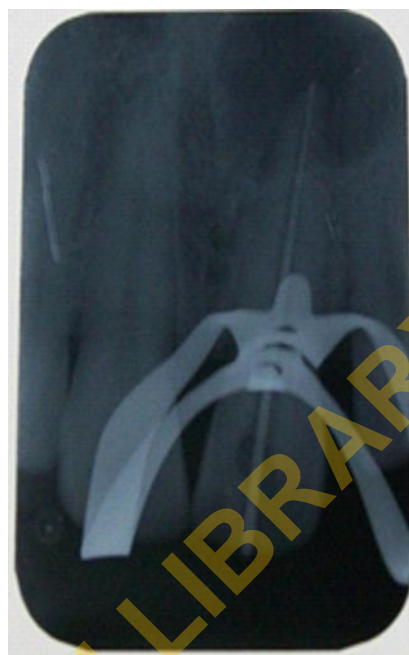


Fig 3: Master cone selection

was dried with paper points and a non-setting calcium hydroxide (Rite Dent Corp. FL, USA) dressing was placed within the canal and access cavity restored temporary with zinc phosphate cement (Prime Dental Manufacturing Inc., Chicago, Illinois). The Patient was

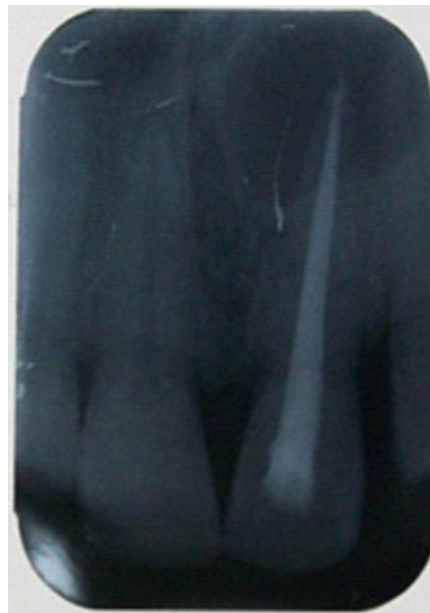

Fig 4: Immediate post-obturation

recalled a week after. Tooth was asymptomatic and not tender to percussion, canal was dry and not foul smelling. After removing the non-setting calcium hydroxide dressing in the canal, the canal was re-instrumented and copiously irrigated and then dried with paper points. Thereafter, the master cone was selected, radiograph taken to ensure it is at the

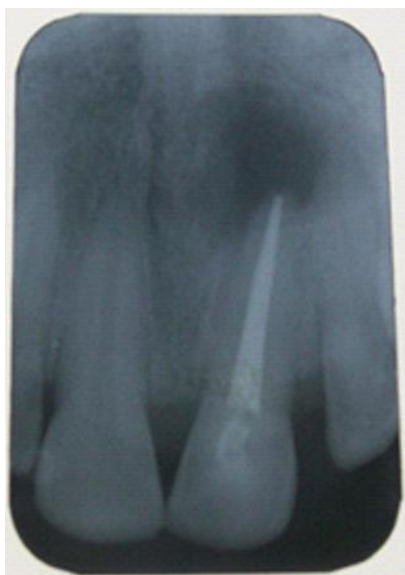

Fig 5: Three (3) months post-periradicular curettage

radiographic terminus (Fig. 3). The root canal system was obturated by lateral compaction of gutta-percha coated with a calcium hydroxide based sealer (Sealapex-Sybron/Keer USA) and access cavity restored with zinc phosphate cement (Fig. 4).

Four weeks later, the patient had periradicular surgery. The cystic lesion was enucleated after exposing the periapical region via a three-sided full thickness mucoperiosteal flap and apical curettage was done. The apical end of the tooth was intact and therefore was not resected (Fig. 6a). Post-operative instructions were given and patient placed on Dalacin C (a brand of

Clindamycin) 300mg 12 hourly for 5 days and diclofenac sodium 50mg 8 hourly for 4 days to be taken after food. Patient was reviewed 24 hours post-operatively and a week to remove sutures. Subsequent follow up was done after a month, three months (Fig. 5) and at six months. The excised specimen was sent to oral pathology laboratory for histopathological examination, the result of which came as periapical cyst.

A month after the surgery, non-vital walking bleaching of discoloured tooth was commenced using a mixture of sodium perborate and 30% hydrogen peroxide. The gutta percha was reduced to 2mm below the cervical margin of the tooth, adequate toileting and drying of cavity done. A layer of hard setting cement such as glass ionomer cement was placed over the gutta percha (to act as a barrier preventing percolation of the superoxide radicals). A thick paste of the sodium perborate and 30% hydrogen peroxide was then placed within the access cavity and sealed off with zinc phosphate cement. After four applications of bleaching agents at one week interval, a satisfactory shade comparable to the adjacent tooth was obtained. The access cavity was restored with composite resin.

At three month post operative review visit, the tooth was clinically asymptomatic and radiographically, there was evidence of healing at periapical region evidenced by reduction in size of the radiolucency and loss of sclerotic margin in comparison with pre-operative radiograph.

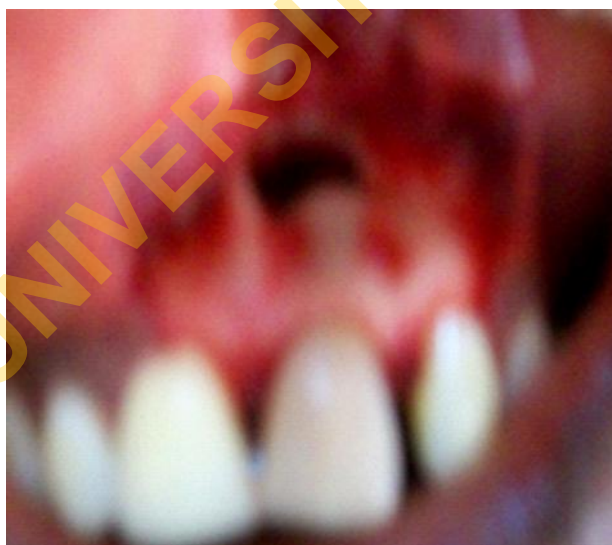

Fig 6a

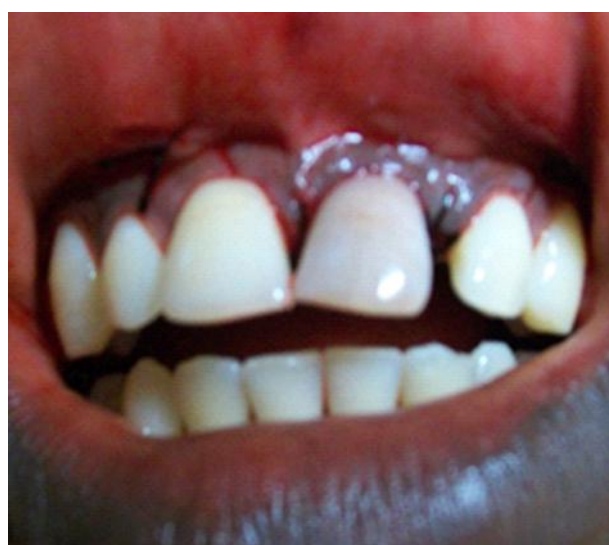

Fig 6b

Figure 6a&6b showing patient's clinical photograph immediately after cystic enucleation with curettage, and immediate post-operative with replacement of mucoperiosteal flap held in place by sutures respectively

DISCUSSION

The average root canal length in a population is an important aid in working length determination during root canal therapy, most especially when using digital tactile method. The average length of maxillary central incisor reported by Black⁶ in 1902 was 22.5 mm with a range between 18 and 27 mm. Bjorndal *et al.*⁷ in 1974, found an average length of 23.7mm and a maximum length of 27.3mm in their study. Kims *et al.*¹⁰ in 2005, while comparing the root canal length between Asians and Caucasians, reported mean value of maxillary central incisors' canal length of 22mm and 23.5mm for Asians and Caucasians respectively with a significant difference of 1.5mm.

There have been some case reports of unusually long maxillary central incisors in the literature. In 1988, Booth¹¹ reported a case of extracted maxillary central incisor in a 31 year old female Australian, measuring 30 mm. Cohenca *et al.* in 1996,¹² reported endodontic retreatment of unusually long maxillary left and right central incisors with working lengths of 32mm and 33mm respectively.

The patient described presents a maxillary central incisor with working length of 29mm, which falls in the upper limit of reported normal range,^{6,7} it is however unusually long based on our clinical experience. Since the quoted normal range of canal lengths were from studies in Caucasian population and racial differences in canal lengths have been reported¹⁰, this case might actually be unusually long for our population.

CONCLUSION

Though other studies have reported longer canal length and the case presented represents an upper limit of the normal as reported by some studies, it is still unusual in our environment. Therefore, adequate preparation must be made for proper management of such cases when encountered.

RECOMMENDATION

Since studies on teeth anatomy, morphology and their lengths were mostly based on Caucasian^{7,10} and very few Africans^{8,13} populations, there is still a need to carry out more studies in African populations to determine the normal range of root canal length for Africans.

REFERENCES

1. **Sponchiado EC Jr.**, Ismail HA, Braga MR, de Carvalho FK, Simoes CA. Maxillary central incisor with two root canals: A case report. *J Endod* 2006; 32: 1002- 1004.
2. **Lin WC**, Yang SF, Pai SF. Nonsurgical endodontic treatment of a two-rooted maxillary central incisor. *J Endod* 2006; 32: 478-481.
3. **Genovese FR**, Marsico EM. Maxillary central incisor with two roots: A case Report. *J Endod* 2003; 29: 220-221.
4. **Cimili H**, Kartal N. Endodontic Treatment of Unusual central Incisors. *J Endod* 2002; 28: 480-481.
5. **Rodrigues EA**, Silva SJA. A case of unusual anatomy: maxillary central incisor with two root canals. *Int J Morphol* 2009; 27(3): 827-830.
6. **Black GV**. Descriptive anatomy of human teeth. 4th ed. Philadelphia: S.S, White Dental Manufacturing Co., 1902: 16-21.
7. **Bjorndal AM**, Henderson WG, Skidmore AE, Kellner FH. Anatomic measurements of human teeth extracted from males between the ages 17 and 21 years. *Oral Surg* 1974; 38: 791-803.
8. **Okpo E**, Akkpata E. Tooth lengths in Nigerians. *Int. Endo J* 1986;19:248-252.
9. **Weine FS**. Endodontic therapy. 2nd edn, p.153, C.V. Mosby Company. St. Louis. 1976
10. **Kim E**, Fallahragtegar A, Hur Y-Y, *et al.* Difference in root canal length between Asians and Caucasians. *Int Endod J* 2005; 38: 149-151.
11. **Booth JM**. The Longest tooth? *Aust Endod News* 1988;13: 17-19.
12. **Cohenca N**, Karni S, Heling I, Rotstein I. Endodontic retreatment of unusually long maxillary central incisors. *J. Endod* 1996; 22: 269-271.
13. **Folaranmi A**. A Comparative study of the morphology of the root and root canals of permanent maxillary incisors in Nigerians. Dissertation submitted to West African College of Surgeons, July 1997.