

HISTOPATHOLOGICAL PATTERN OF PRIMARY OVARIAN NEOPLASMS IN SOUTH-WESTERN NIGERIA

Ajani MA¹ (MBBS, FMCPATH, FWACP), Aramide KO¹ (MB.ChB, FMCPATH), Salami A² (MBBS, FMCPATH), Okolo CA² (MBBS, FMCPATH).

¹Department of Histopathology, Babcock University, Ilishan- Remo, Ogun state, Nigeria.

²Department of Pathology, University College Hospital, Ibadan, Nigeria

Corresponding Author:

Dr Mustapha A. Ajani, Department of Histopathology,
Babcock University, Ilishan-Remo, Ogun state, Nigeria.

E-mail: ajanimustapha@yahoo.com,

Tel: +2348039125255

Abstract

Background: Ovarian tumours are common forms of neoplasms in women. This study aims to determine the histopathological pattern of primary ovarian neoplasms in South-western Nigeria.

Method: A retrospective study was undertaken to review the histopathology reports of all primary ovarian neoplasm specimens submitted to the Department of Pathology, University College Hospital, Ibadan from January 1991 to June 2013. Patients' biodata were extracted from the request forms and surgical day books.

Results:

There were 821 cases of primary ovarian neoplasms. 359 (43.7%) cases were surface epithelial neoplasms which were found in patients with age range 10-89 years. Three hundred and thirteen (38%) cases of germ cell tumour were found in patients with age range 0-70 years. One hundred and forty-six (17.8%) cases of sex cord stromal tumour were found in patients with age range 0-99 years.

Mature Cystic Teratoma was the most common (54.7%) among benign ovarian neoplasms with 20-29 years being the age range with highest tumours while serous cystadenocarcinoma was the most common (33.2%) primary malignant ovarian neoplasms with 50-59 years being the age range with highest tumours.

Conclusion:

Surface epithelial tumours were the most common ovarian neoplasm followed by germ cell tumours. This pattern is observed in most parts of Nigeria, some African and Asian countries, and in the Western world.

Keywords:

Histopathology, Ovary, Primary Neoplasms, Ibadan.

Introduction

Ovarian tumour, a common neoplasm in women, can present as either benign or malignant tumor. About 80% of ovarian neoplasms are benign and these occur mostly in young women between the ages of 20 and 45 years¹. The malignant tumours are more common in older women between the ages of 40 and 65 years¹. Ovarian carcinoma is the fourth most common female cancer and the fourth leading cause of cancer related deaths in females^{2,5}. Ovarian tumours are generally difficult to detect until they are advanced stages or are large in size. This is because most cases are asymptomatic and the tumour often manifests in advanced stages. At present there is no definite screening program for ovarian tumours as obtained in cervical cancer⁶.

The cause of ovarian neoplasms have been based on hypotheses proposed by Fathalla⁷. Determination of various histological patterns of primary ovarian tumour is very important in diagnosis, treatment as well as prognostication⁵. Prognosis of the tumours can also be predicted from the degree of differentiation of the tumours⁵. The stage and laterality of the tumour also indicates their nature; for example, tumours in the sex cord stromal category are almost always confined to a single ovary⁵.

This study attempts to examine the epidemiology of this neoplasm in our local population and thus understand the contribution of this tumour to morbidity and mortality in the female population.

Method

This is a retrospective study done in the Department of Pathology of University College Hospital Ibadan from January 1991 to June 2013 (a period of twenty-two and half years). All histologically confirmed cases of primary neoplasms of the ovary seen were used for the study.

All cases whose slides and blocks could not be retrieved were excluded from the study.

The demographic data and clinical history of these cases were obtained from the request forms, case notes, surgical daybooks, post-mortem records and Cancer Registry data. These were cases diagnosed following total abdominal hysterectomy, bilateral salpingo-oophorectomy, unilateral oophorectomy, omentectomy, and multiple peritoneal biopsies and post-mortems at the University College Hospital between January 1991 and June 2013.

Haematoxylin and Eosin (H&E) stained histopathology slides of each case were reviewed. New haematoxylin and eosin stained sections were obtained from archival paraffin blocks where necessary. All cases of primary ovarian tumours were classified according to the 2003 WHO histological classification of tumours of the ovary.⁸

The data were analyzed in terms of frequency, age distributions and histological subtypes using Statistical Package for Social Sciences version 20. The data for these patients were presented in tables and figures.

Ethical clearance for the study was obtained from the Joint University of Ibadan/University College Hospital Ethical Review Committee according to Helsinki Declaration 1975, as revised in 2000.

Results

A total of 821 cases of primary ovarian tumours were used for the study. Five hundred and ten (62.1%) were benign, 6 (0.7%) were borderline and 305 (37.1%) were malignant. Majority, 353 (43.0%) of cases were found in the right ovary. There were 282 (34.3%) cases found on the left and the remaining cases 186 (22.7%) were bilateral.

The primary ovarian tumours were categorized into 3 main groups. Surface epithelial tumours constituted the majority of the ovarian neoplasms with 359 (43.7%) cases, followed by Germ cell tumours, which constituted 313 (38.1%) cases. Sex cord stromal tumours constituted 146 (17.8%) cases. Other primary ovarian tumours in this study were malignant mixed mullerian tumour which constituted 3 (0.4%). Among the 510 benign tumours, mature cystic teratoma was the commonest, comprising 279 (54.7%) cases followed by serous cystadenoma, which comprised 100 (19.6%) cases. Mature cystic

teratoma is the single commonest ovarian neoplasm. Serous Cystadenocarcinoma was the commonest primary malignant tumour, comprising 117 (38.4%) of all malignant neoplasms, followed by granulosa cell tumour, which comprised 91 (29.8%) cases.

The age group of the patients ranged from the youngest being 4 years and the oldest being 92 years with mean age of 39.2 (S.D= 15.8) years. The peak age of occurrence of ovarian neoplasms was in the fourth decade (Figure 1). The peak ages of benign and malignant ovarian neoplasms were 3rd and 6th decades respectively.

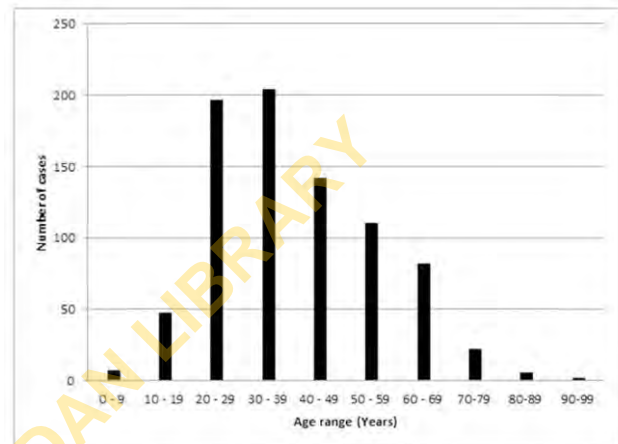


Figure 1: Age distribution of 821 patients with primary ovarian neoplasms

There were 359 (43.7%) cases of surface epithelial neoplasms which were found between 10-89 years and the highest numbers were seen in the age group of 40-49 years. No case of surface epithelial tumours was found below 10 years of age. There were three hundred and thirteen (38%) cases of germ cell tumour found and the highest number of them were seen in the age group of 20-29 years. One hundred and forty-six (17.8%) cases of sex cord stromal tumour were found and the highest numbers of them were seen in the 30-39 years age group. Three (0.4%) cases of primary malignant mixed mullerian tumour were found between 40-69 years.

Mature cystic teratoma was the most common (54.7%) among benign ovarian neoplasms with 20-29 years being the age group with highest tumours and serous cystadenocarcinoma was the most common (33.2%) among the malignant ovarian neoplasms including the secondary tumours with 50-59 years being the age group with highest tumours.

Surface Epithelial Tumours (SET)

These tumours comprised the largest group of the total ovarian neoplasms 359 (43.7%) with 174 (48.5%) benign, 6 (1.7%) borderline and 179 (49.9%)

malignant cases

Serous tumours were the commonest comprising of 233 (27.1%) of all primary ovarian neoplasm and 64.9% of all surface epithelial tumours. Among the serous tumours, serous cystadenocarcinoma was the commonest malignant epithelial tumour comprising 117 (14.2%) of primary ovarian neoplasms and 32.6% of surface epithelial tumours (Figure 2).

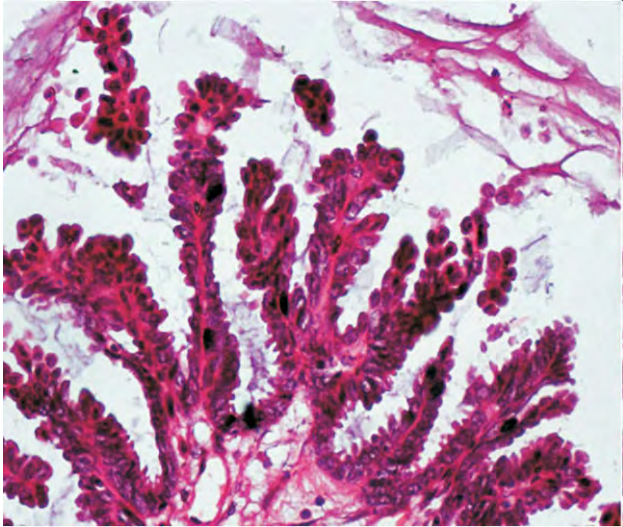


Figure 2: Photomicrograph showing Papillary Serous Cystadenocarcinoma disposed predominantly in papillary pattern (Haematoxylin and eosin, X400)

Serous cystadenoma was the commonest benign surface epithelial tumours comprising 100 (27.9%) of SET and 12.2% of primary ovarian neoplasms. Serous cystadenofibroma was observed in 13 cases with 3.6% of total SET and 1.6% of primary ovarian tumours.

There were 6 cases of borderline tumour, out of which, borderline serous tumour comprised 3 (0.8%) of SET

Mucinous neoplasms were the second commonest among SET comprising 99 (12.1%) of all primary ovarian tumours and 27.6% of SET. Mucinous cystadenocarcinoma was the commonest comprising 51(14.2%) of SET and 6.2% of primary ovarian neoplasms. Mucinous cystadenoma comprised 46 (12.8%) of SET and 5.6% of primary ovarian neoplasms. Borderline mucinous tumour was observed in 2 cases with 0.6% of total SET and 0.2% of total primary ovarian neoplasms.

Brenner tumours comprised 16 (4.5%) of SET and 1.9% of all primary ovarian neoplasms. Benign Brenner tumour was the commonest seen and comprise 14 (3.9%) of SET and 1.7% of all primary ovarian tumours. Only one case of borderline Brenner and malignant Brenner was observed each with 0.3% of total SET and 0.1% of total primary

ovarian tumour. Endometrioid carcinoma was observed in 9 cases with 2.5% of total SET and 1.1% of primary ovarian tumours.

Two cases (one each of benign Brenner tumour and mucinous cystadenoma, and malignant Brenner Tumour and mucinous cystadenocarcinoma) of mixed surface epithelial tumours were observed comprising 0.6% of total SET and 0.2% of total primary ovarian tumour.

Germ Cell Tumour (GCT)

Germ cell tumours comprised the second commonest tumour 313 (38.1%) of all primary ovarian neoplasms. Two hundred and eighty one (89.8%) cases were benign and 32 (10.2%) cases were malignant. Teratoma constituted 289 (92.3%) of GCT and 35.2% of total primary ovarian neoplasms. Mature cystic teratoma was the commonest 279 (89.1%) of the GCT, 34.0% of total primary ovarian neoplasms and 96.5% of total teratomas (Figure 3).

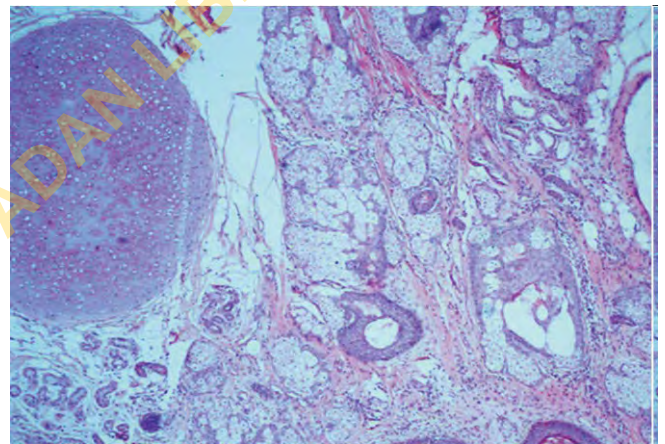


Figure 3: Photomicrograph of a case of Mature Cystic Teratoma showing various tissue components- hair follicles, sebaceous glands, sweat glands and cartilage. (Haematoxylin and eosin, X100)

There were 7 cases of Immature Teratoma constituting 2.4% of total teratoma and 2.2% of GCT. Only one case each of Struma Ovarii, carcinoid, and Teratoma with malignant transformation (squamous carcinoma) were observed. There were 10 cases of Yolk Sac Tumour constituting 4.5% of GCT and 1.2% of total primary ovarian neoplasms. Six cases of choriocarcinoma were seen constituting 1.9% of GCT and 0.7% of total primary ovarian tumours. There were 3 cases of dysgerminoma constituting 1.0% of GCT and 0.4% of total primary ovarian neoplasms. Only one case of mixed germ cell tumour (Yolk sac tumour with Mature cystic teratoma) was seen.

Sex Cord Stromal Tumour (SCST)

This group of tumours comprised 146 (17.8%) of all primary ovarian tumours. Fifty-five cases of SCST were benign representing 37.7% of SCST and 6.7% of all primary ovarian neoplasms. There were 91 cases of SCST that were malignant constituting 62.3% of all SCST and 11.1% of total primary ovarian neoplasm. Fibrothecoma was the commonest (32 cases) sex cord stromal tumour constituting 21.9% of total SCST, and 3.9% of all primary ovarian neoplasms followed by fibroma which constituted 16 (11%) of SCST and 1.9% of all primary ovarian tumours. Other benign SCST included 5 cases of thecoma, one case of Leydig cell tumour, and a case of Sertoli-Leydig cell tumour.

The commonest malignant SCST was Granulosa cell tumour constituting 91(62.3%) of SCST and 11.1% of primary ovarian neoplasms (Figure 4).

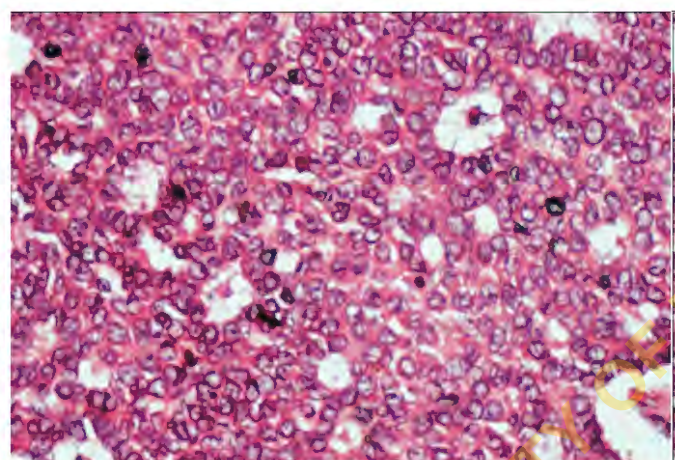


Figure 4: Photomicrograph of a case of Granulosa Cell Tumour showing tumour cells arranged in sheets punctuated by small follicle-like structures (Call-Exner bodies) (Haematoxylin and eosin, X400)

Of 91 cases of granulosa cell tumour, adult granulosa cell tumour (AGCT) constituted 87.9% of granulosa cell tumour, 54.8% of all SCST and 9.7 % of total primary ovarian tumour. Juvenile granulosa cell tumour (JGCT) constituted 21.1% of all granulosa cell tumours, 7.5 % of SCST and 1.3% of all primary ovarian tumours.

Discussion

Benign ovarian tumours were found to be more common than the malignant tumours similar to findings of other studies.^{9-10,12-15} (Table 1)

Table I Comparison of distribution of benign, borderline and malignant ovarian neoplasms seen in the present study with other studies

Author (year)	Location of study	Number	Type of tumour		
			Benign (%)	Borderline (%)	Malignant (%)
Sabageh et al. ⁹ (2012)	Ile-Ife, Nigeria	69	69.6	-	30.4
Onyiaorah et al. ¹⁰ (2011)	Lagos, Nigeria	203	80.3	-	19.7
Ahmad et al. ¹² (2000)	Uttarakhand, Pakistan	855	59.2	3.3	40.8
Hassan et al. ¹³ (2014)	India	131	66.4	9.2	24.4
Pradhan et al. ¹⁴ (2012)	Dharan, Nepal	83	79.5	2.4	18.1
Nabi et al. ¹⁵ (2011)	Lahore, Pakistan	150	74	1.3	24.7
Present study	Nigeria	821	62.1	0.8	37.1

Surface epithelial tumours constituted majority of the primary ovarian neoplasms with 359 (43.7%) cases followed by germ cell tumours of 313 (38.1%). Sex cord stromal tumours constituted 146 (17.8%). These findings were similar to the results of many studies^{2, 5, 9, 11-19, 22- 24} where surface epithelial tumours were found to be the commonest primary ovarian neoplasms followed by germ cell tumours. These findings are however in contrast to what was observed by Onyiaorah et al.¹⁰ where germ cell tumours constituted the commonest (52.7%) ovarian neoplasms followed by surface epithelial tumours constituting 27.6%. Mature cystic teratoma was found to be the most common benign primary ovarian tumour constituting 54.7% of cases of benign tumours followed by serous cystadenoma comprising 19.6%. Mature cystic teratoma is the single commonest ovarian neoplasm constituting 34.0% of total primary ovarian tumours. The finding is similar to results of studies by Sabageh et al.⁹ from Ile-Ife, Nigeria and Obed et al.²² from Maiduguri, Nigeria where mature cystic teratoma was found to be the commonest benign ovarian

tumour constituting 37.7% and 25.0% of total ovarian neoplasms respectively. In Lagos, Nigeria, Onyiaorah et al.¹⁰ reported mature cystic teratoma as the commonest benign ovarian tumour constituting 60.1% of benign ovarian tumours. Similar studies by Hassan et al.¹³, from India and Muzaffar et al.²¹ from Pakistan, showed mature cystic teratoma as the commonest benign ovarian neoplasm constituting 25.8% and 29% of total ovarian tumours respectively. However these findings are in contrast to what was found in some other studies where Serous cystadenoma was the commonest benign ovarian tumour constituting 34.3%, 42.9%, 28.7%, 32.5% and 35% of total ovarian tumours respectively.^{1, 12, 15-17} Table II shows a comparison of the relative frequencies of the six commonest benign tumours in the present study with those in other studies.

Table II Relative frequencies of the six commonest benign primary ovarian tumours in the present study compared with other studies

Benign Ovarian neoplasms	Sabageh et al.⁹ (%)	Pilli et al.¹¹ (%)	Hassan et al.¹³ (%)	Abdullah et al.¹⁶ (%)	Makwana et al.¹⁷ (%)	Present study (%)
Mature Cystic Teratoma	37.7	17	25.8	24.6	18.6	34.0
Serous Cystadenoma	23.2	42.9	19.8	32.5	35	12.2
Mucinous Cystadenoma	5.8	25.5	13.7	9.9	9.3	5.6
Fibrothecoma	4.3	-	-	-	1.4	3.9
Fibroma	-	-	-	4.7	-	1.9
Brenner Tumour	-	-	3.1	-	2.1	1.7

In the current study, Serous cystadenocarcinoma was found to be the commonest malignant ovarian tumour constituting 14.3% of total primary ovarian neoplasms. This finding is similar to the results of studies by Obed et al.²³ and Sabageh et al.⁹ from Nigeria constituting 7.7% and 8.7% of total ovarian tumours respectively. Similarly, studies by Onyiaorah et al.¹⁰ and Umanah et al.²⁵ showed serous cystadenocarcinoma to be the commonest malignant ovarian tumour constituting 42.5% and 50% of malignant ovarian neoplasms respectively. The

finding is however in contrast to results of studies by Hassan et al.¹³ and Muzaffar et al.²¹ where the commonest ovarian neoplasm was found to be mucinous cystadenocarcinoma constituting 13% and 13.1% of total ovarian neoplasms respectively. Endometrioid carcinoma was found in this study to be 1% of total primary ovarian tumours. This finding showed a relatively lower incidence than what was found by Ahmad et al.¹² and Hassan et al.¹³ where it constituted 4.9% and 4.6% of total ovarian tumours respectively. Table III shows a comparison of the

relative frequencies of the six commonest malignant ovarian tumours in the present study, with those in other studies.

Table III Relative frequencies of the six commonest malignant primary ovarian tumours in

Malignant Ovarian neoplasms	Sabageh et al.⁹ (%)	Ahmad et al.¹² (%)	Hassan et al.¹³ (%)	Abdullah et al.¹⁶ (%)	Present study (%)
Serous Cystadenocarcinoma	8.7	12.5	3.1	7.3	14.3
Granulosa Cell Tumour	7.2	2.8	5.6	1.8	11.1
Mucinous Cystadenocarcinoma	4.3	6.4	13	3.4	6.2
Yolk Sac Tumour	-	0.9	1.6	1.0	1.7
Endometrioid Carcinoma	-	4.9	4.6	-	1.1
Immature Teratoma	-	0.7	-	0.5	0.8

The age range of cases in this study is 4-92 years with the mean age being 39.2 years. Similar results were reported by Ahmad et al.¹² and Pradhan et al.¹⁴ Pilli et al.¹¹ and Sabageh et al.⁹ in their studies, reported the youngest patients being 8 months and 12 months respectively. The peak age of occurrence of ovarian neoplasms is in the fourth decade which is similar to the reports of Hasan et al.¹³

Benign ovarian neoplasms were found in the youngest patients (two cases of mature cystic teratoma and one case of fibrothecoma) while the oldest patient had malignant tumour (one case of granulosa cell tumour). This finding is similar to reports from other studies where benign tumours were seen in the youngest patients and malignant tumours in the oldest patients.^{2, 9-10, 12, 16} This finding is however in contrast to what was found by Pradhan et al.¹⁴ where the youngest patient (10 years) was found to have presented with a Dysgerminoma (malignant) and the oldest patient (86 years) with serous cystadenoma.

The peak age incidence of benign ovarian tumours in this study was 20-29 years age group (3rd decade) with Mature Cystic Teratoma being the most frequent tumour which is similar to the report of Onyiorah et al.¹⁰ The peak age incidence of malignant ovarian neoplasms was 50-59 years age group (6th decade) with Serous Cystadenocarcinoma being the most common malignant tumour occurring in this age group. These findings are similar to reports of other studies.^{9, 11-12, 15-17}

Unilateral involvement of ovarian neoplasms was more common than bilateral involvement in the current study, and is similar to the findings of other studies.^{9, 14} Involvement of right ovary was more than the left and is similar to what was found by Sabageh et al.⁹ and Tyagi et al.²⁶ This finding is however in contrast to what was found by Pradhan et al.¹⁴ where left ovarian involvement was more than the right.

Conclusion

This study has shown that benign ovarian neoplasms are more common than malignant tumours. Surface Epithelial Tumours were the commonest group (occurring in the age group 10-89 years) closely followed by Germ Cell Tumours in the age group 0-79 years similar to the Western and local data from other medical institutions. Benign surface epithelial tumours occurred at a younger age than their malignant counterparts. Germ cell tumours occurred in much younger women. Malignant ovarian neoplasms were more common in patients above 50 years. Germ cell tumours were most common tumour up to 30 years. Sex Cord Stromal Tumours were also common with Granulosa cell tumour accounting for the majority. Unilateral involvement of ovarian neoplasms was more common than bilateral, and involvement of right ovary was more than the left. Mature cystic teratoma was the commonest benign ovarian neoplasm while the commonest malignant tumour was serous cystadenocarcinoma.

Conflict of interest

None declared

Acknowledgements

We thank Mr SP Otegbade of the Department of Pathology, University College Hospital for the technical assistance he rendered with the slides used for this study.

References

1. Lora HE, Edyta CP, Husain AN. The Female genital tract. In Kumar V, Abbas AK, Fausto N, Aster JC (Eds.) Robbins and Cotran's Pathologic Basis of Disease, 8th edition. Philadelphia, Saunders-Elsevier, 2010;1039-1052.
2. Swamy GG, Satyanarayana N. Clinicopathological analysis of ovarian tumours- A study on five years samples. Nepal Med Coll J 2010; 12(4): 221-223
3. Rashid S, Sarwas G, Ali A. A Clinicopathological study of ovarian cancer. Mother Child 1998; 36: 17-25.
4. Tortolero L, Mitchell FM, Rhodes HE. Epidemiology and screening of ovarian cancer Obstet Gynecol Clin North Am 1994; 21:63-75
5. Yasmin S, Yasmin A, Asif M. Clinicohistological pattern of ovarian tumours in Peshawar region. J Ayub Med Coll Abbottabad 2008; 20(4):11-13.
6. Shoail I, Hayat Z, Saeed S. A comparative analysis of frequency and patterns of ovarian tumours at a tertiary care hospital between two different study periods (2002-2009). J Postgrad Med Inst 2012; 26(2):196-200.
7. Fathalla MF. Incessant ovulation: a factor in ovarian neoplasia? Lancet 1971; 2: 163-165.
8. Tavassoli FA, Devilee P. Pathology and genetics. Tumours of the breast and female genital organs. Lyon, IARC Press, 2003: 114-115.
9. Sabageh D, Olaofe OO, Sabageh AO. An Analysis of the Clinicopathologic Characteristics of Ovarian Tumours in Ile-Ife, Nigeria. Ann Trop Pathol 2012; 3(2):99-106.
10. Onyiaorah IV, Anunobi CC, Banjo AA, Abdulkareem AF, Nwankwo KC. Histopathological patterns of ovarian tumours seen in Lagos University Teaching Hospital: a ten year retrospective study. Nig Q J Hosp Med. 2011; 21(2):114-118.
11. Pilli GS, Suneeta KP, Dhanded AV, YenniVV. Ovarian tumours: a study of 282 cases. J Indian Med Assoc 2002; 100:420, 423-424, 427
12. Ahmad Z, Kayani N, Hassan SH, Muzaffar S, Gill MS. Histological pattern of ovarian neoplasms. J Pak Med Assoc. 2000; 50(12):416-419.
13. Hasan Y, Rizvi G, Pandey HS. Histological pattern of Ovarian Tumours in a Tertiary care Hospital in Kumaon Region of Uttarakhand: A five year Retro-Pro prospective Study. JEMDS 2014; 3(10):2536-2542.
14. Pradhan A, Sinha AK, Upreti D. Histopathological patterns of ovarian tumours at BPKIHS. Nepal Med Coll J. 2012; 10(2):87-97.
15. Nabi U, Naseem N, Tanvir I, Riaz S. Clinicopathological Pattern in 150 Females Presenting with Benign and Malignant Ovarian Tumours. Pak J Med Health Sci 2011; 5(4):645-650.
16. Abdullah LS, Bondaqji NS. Histopathological pattern of ovarian neoplasms and their age distribution in the western region of Saudi Arabia. Saudi Med J. 2012; 33(1):61-65.
17. Makwana HH, Maru AM, Lakum NR, Agnihotri AS, Trivedi NJ, Joshi JR. The relative frequency and histopathological pattern of ovarian masses- 11 year study at tertiary care centre. Int J Med Sci Public Health 2014; 3:81-84.
18. Asraf A, Shaikh AS, Ishfaq A, Akram A, Kamal F, Ahmad N. The Relative frequency and Histopathological Pattern of Ovarian masses. Biomedica. 2012; 28:98-102.
19. Jha R, Karki S. Histological pattern of ovarian tumours and their age distribution. Nepal Med Coll J. 2008; 10(2):81-85.
20. Gupta N, Bisht D, Agarwal AK, Sharma VK. Retrospective and prospective study of ovarian tumours and tumour-like lesions. Indian J Pathol Microbiol. 2007; 50(3):525-527
21. Muzaffar M, Malik IA, Ashraf S. A clinicopathological study of 107 ovarian tumours. J. Pak. Med Assoc. 1987; 37: 194-197.
22. Obed JY, Khali MI, Ekanem ED. Histological types of ovarian tumours as seen in an African teaching hospital in north-eastern Nigeria. J Obstet Gynaecol. 1999; 19(5):526-528.
23. Dhakal HP, Pradhan M. Histological Pattern of Gynecological Cancers. J Nepal Med

- Assoc. 2009; 48(176):301-305.
24. Zaloudek C. Tumours of the ovary. In: Fletcher CDM. Diagnostic Histopathology. 2nd ed. Elsevier, London; 2002:567-627.
 25. Umanah IN, Ugiagbe EE, Olu-Eddo AN. Female genital tract malignancies in a Niger-Delta region of Nigeria. *Ibom Med J.* 2013; 6 (1):23-28.
 26. Tyagi SP, Maheswari V, Tyagi N, Saxena K, Hameed F. Solid tumours of the ovary. *J Indian Med Assoc.* 1993; 91 (9):227-230.

UNIVERSITY OF IBADAN LIBRARY