

Reconstruction of a complex anterior abdominal wall defect with autologous tissues – a case report

Odeyinde S.O.¹, Ademola S.A.², Oluwatosin O.M.²

¹Clinical Fellow in Plastic Surgery, Department of Plastic Surgery, St Thomas' Hospital, London, UK

²Division of Plastic and Reconstructive Surgery, Department of Surgery, University College Hospital, Ibadan, Nigeria.

Correspondence:

Samuel Odeyinde, FWACS(Plast), MRCS(Eng)

15 Tower Close, East Grinstead, West Sussex RH19 3RT, UK.

Email address: bodmanx@mail.com

Submitted: 9 August 2011

Accepted: 13 September 2011

Summary

Background: The anterior abdominal wall is an important complex composite structure that poses a challenge to the reconstructive surgeon. Defects produced from infection, herniation, tumour extirpation or trauma, are often encountered. Different techniques of reconstruction have been described using autologous tissues and prosthetic materials with varying results, availability and cost implications. The use of totally autologous tissues presents a readily available reconstructive option that has been shown to be associated with a satisfactory outcome and low morbidity. In this report, we describe the use of autologous tissues for the reconstruction of a major abdominal wall defect.

Method: This communication describes our experience of the use of purely autologous tissues for a full thickness anterior abdominal wall defect, presented as a case report.

Result: The initial result that was obtained confirms that this is a useful technique with a satisfactory outcome with minimal morbidity.

Conclusion: Utilizing purely autologous tissues, avoids most of the complications of the other techniques, is readily available, relatively cost-effective (especially advantageous in the developing country) and is less technically demanding.

Keywords: Abdominal wall tumour, Fascia lata, Omentum, Skin graft

Introduction

The anterior abdominal wall is a complex fascio-muscular structure, defects of which may be congenital or acquired. Various procedures exist to reconstruct these defects with varying results, availability and cost. In this report, we describe the use of autologous tissues for the reconstruction of a major abdominal wall defect.

Case report

A 40-year-old male Nigerian presented to the Division of Plastic Surgery, University College Hospital, Ibadan, with an 18-year history of a recurrent anterior abdominal swelling. Examination revealed an extensive 24 x 30cm periumbilical mass and an inferior 10 x 10cm extension with the scar of the previous excision in between, figure 1. The mass appeared to arise from the tissues of the anterior abdominal wall. A biopsy had revealed a dermatofibrosarcoma protuberans.

He underwent wide local excision with a 3cm margin including muscle and fascia leaving a full thickness defect. The greater omentum was brought out on the left gastro-epiploic vessels. A 25 x 15cm sheet of fascia lata was harvested from the right thigh and secured

to the musculo-aponeurotic layer at the edge of the defect with non-absorbable sutures, figure 2. A window was deliberately left to accommodate the vascular pedicle of the omental flap to prevent strangulation, figure 2. This was recognized, at the time, as a potential weak point. The omental flap was laid on the fascia lata graft and its edges were sutured to the surrounding subcutaneous fat layer. A split thickness skin graft was harvested from the contralateral thigh and sutured to the surrounding skin over the omental flap to provide skin cover. The skin graft was fenestrated and secured with non-adherent dressings and a sponge. The fascia lata donor site was closed over a drain. The patient had an uneventful post-operative course and did not require intensive care unit admission. There was a 100% skin graft take at 5 days. Figure 3 shows the post-operative appearance after a few weeks.

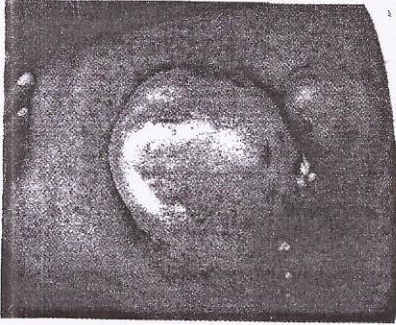

Figure 1: Abdominal wall tumour

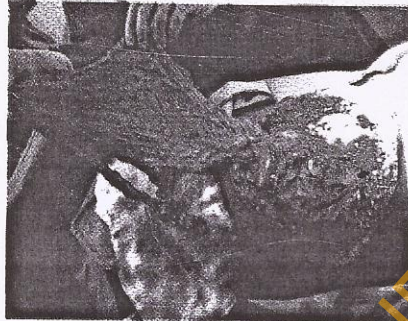

Figure 2: Abdominal wall defect and omental flap




Figure 3: Several weeks post-operatively

The fascia lata provided the fascial layer for strength and the omental flap provided a vascular bed for skin cover. There was no donor site (fascia lata or skin graft) morbidity. The histology of the excised specimen, surprisingly, came back as a malignant peripheral nerve sheath tumour. Unfortunately, he developed a hernia after three months of follow up, figure 4. However, there was no evidence of local or regional recurrence of the tumour.




Figure 4: Same patient after development of hernia

At exploration, the intraperitoneal contents were found to be herniating through the defect in the fascia lata that also transmitted the vascular pedicle of the omental flap. The omental flap was deemed to be independent of its pedicle by clamping the latter, which was then divided. Closure of this secondary fascial defect was effected with more fascia lata, repairing the hernia. He was lost to follow up subsequently but returned with metastatic disease which resulted in mortality.

Discussion

Resection of an abdominal wall tumor often leads to a full thickness defect. Composite reconstruction is usually required, with combination of autologous tissues and synthetic materials. The current techniques of reconstruction all have their drawbacks: the transferring of a flap, such as a free or pedicled tensor fasciae latae flap, creates a donor site with potential morbidities and is also time-consuming and reserved for the very complex situation.¹ Components separation and its modifications^{2,3} have similar disadvantages. Non-absorbable synthetic meshes, such as Prolene and Marlex, are intolerant to infection and sometimes results in an excessive foreign body reaction. Prosthetic material use is contra-indicated in the contaminated operative field in which case reconstruction with autologous tissue is preferred.¹ Bioprosthetic materials, such as human acellular dermal matrix (AlloDerm), have been combined with large thigh flaps to reconstruct complex abdominal defects which have irradiated fields and potential contamination with relatively minor complications.⁴

Hamilton first described autologous fascia lata for abdominal wall reconstruction in 1956.⁵ However, it was largely abandoned until Disa et al. in 1998⁶ re-applied it and reported a hernia rate of 9%. One major advantage of fascia lata is that it does not have to be removed in cases of wound infection or wound breakdown with graft exposure. Drawbacks, however, are that they exist in a limited supply and can result in donor site morbidities such as seroma. The patient's fascia lata donor site did not have any complication.

Greater omentum provides well vascularised tissue for wound coverage. It has strong resistance against infection and is very malleable. It is approximately 25 x 35cm and has a capacity for further lengthening.⁷ The omentum has been used as an interposition flap for abdominal wall reconstruction with fascia lata⁸ and prosthetic material.^{9,10} It also provides a vascular bed for a skin graft.


The only morbidity in this case was the hernia after three months. This was found to be due to transmitted intra-peritoneal contents via the fascia lata window that served as exit for the omental pedicle. The "exit hernia" rate for pedicled omental flaps has been documented as 10% in the literature.¹¹ To base the omental flap on the right gastro-epiploic vessels instead of those on the left may have prevented this complication. The presence of the liver on the right side may have prevented the herniation.¹² Tunneling the omental flap subcutaneously to the recipient site through an adjacent but separate opening through muscle may also have prevented the herniation. This has been described with a muscle splitting dissection lateral to the semilunar line, bringing out the omental pedicle in an oblique direction.¹²

Utilizing purely autologous tissues, as we did, avoids most of the complications of the other techniques. It is readily available, is relatively cost-effective, especially advantageous in the developing country, and is less technically demanding. This case report further reinforces the fact that this technique is robust and reliable.

References

1. de Vries Reilingh TS, Bodegom ME, van Goor H, Hartman EH, van der Wilt GJ, Bleichrodt RP. Autologous tissue repair of large abdominal wall defects. *Br J Surg* 2007; 94: 791-803.
2. Ramirez OM, Ruas E, Dellon AL. 'Components separation' method for closure of abdominal wall defects: an anatomic and clinical study. *Plast Reconstr Surg* 1990; 86: 519-526.
3. Maas SM, de Vries Reilingh S, van Goor H, de Jong D, Bleichrodt RP. Endoscopically assisted 'components separation technique' for the repair of complicated ventral hernias. *J Am Coll Surg* 2002; 194: 388-390.
4. Lin SJ, Butler CE. Subtotal thigh flap and bioprosthetic mesh reconstruction for large, composite abdominal wall defects. *Plast Reconstr Surg* 2010; 125: 1146-1156.
5. Hamilton JE. Free matted fascia lata patches in the repair of large abdominal incisional hernias. *Am Surg* 1956; 22: 217-226.
6. Disa JJ, Goldberg NH, Carlton JM, Robertson BC, Slezak S. Restoring abdominal wall integrity in contaminated tissue-deficient wounds using autologous fascia grafts. *Plast Reconstr Surg* 1998; 101: 979-986.
7. Das SK. The size of the human omentum and the methods of lengthening it for transplantation. *Br J Plast Surg* 1976; 29:170-174.
8. Adebamowo CA, Oluwatosin O. Anterior abdominal wall reconstruction with fascia lata. *West Afr J Med* 2001; 20: 231-233.
9. El-Muttardi N, Lancaster K, Ng R, Mercer D. The sandwich omental flap for abdominal wall defect reconstruction. *Br J Plast Surg* 2005; 58: 841-844.
10. Gu Y, Tang R, Gong DQ, Qian YL. Reconstruction of the abdominal wall by using a combination of the human acellular dermal matrix implant and an interpositional omentum flap after extensive tumor resection in patients with abdominal wall neoplasm: a preliminary result. *World J Gastroenterol* 2008; 14: 752-757.
11. Hultman CS, Carlson GW, Losken A, et al. Utility of the omentum in the reconstruction of complex extraperitoneal wounds and defects. *Ann Surg* 2002; 235: 782-795.

12. Wong CH, Tan BK, Koong HN, Lim CH, Chia SJ, Song C. Use of the omentum flap as additional soft-tissue cover for abdominal wall defects reconstructed with Gore-Tex. *Plast Reconstr Surg* 2005; 116: 1715-1720.



Abstracts of 17th annual scientific conference of Nigerian Association of Plastic Reconstructive and Aesthetic Surgeons and of 5th biennial scientific conference of Nigerian Burn Society held at Ibadan on 21-23 September 2011

1.
BREAST RECONSTRUCTION FOLLOWING MASTECTOMY AT NATIONAL ORTHOPAEDIC HOSPITAL, ENUGU

Ogbonnaya IS, Uduetue AO, Enyanwuma IE
National Orthopaedic Hospital Enugu

BACKGROUND: The reconstruction of the breast following mastectomy using autologous tissue has been an on going procedure at national orthopaedic hospital Enugu. Transverse rectus abdominal muscle flap and latissimus dorsi musculocutaneous flap are the flaps commonly used. The results have been quite good.

METHOD: Case series of five patients that had immediate reconstruction after mastectomy. Folders were used

RESULT: The results have been quite good except for one that had complete flap necrosis. None of the patients has come back for nipple areola reconstruction

CONCLUSION: Transverse rectus abdominus muscle flap and latissimus dorsi musculocutaneous flaps are good flaps in the armamentarium of plastic surgeon for postmastectomy breast reconstruction. The results in National orthopaedic hospital Enugu have been quite good.

2.
THE SYRINGE SUCTION DRAIN- A UNIQUE IMPROVISION IN RURAL PLASTIC SURGERY PRACTICE.

Esezobor EE, Okomayin AA

Department of Surgery, Irrua Specialist Teaching Hospital, Irrua Edo State

BACKGROUND: A closed suction drain is what is desired when a drain is needed in surgical practice. However, they are luxury in rural plastic surgery practice. The study highlights how Syringes had become a reliable substitute.

METHOD: This is a prospective study of the surgical outcome of patient who had various plastic surgical procedures between January 2010 and June 2011 with various sizes of syringes and feeding tubes/ drip set used as drain system.

RESULT: A total of 37 surgeries that requires a drain were done. There were 26(70.2%) males and 11(29.8%) females. Of the total number, 8(21.6) were children. The average duration the drain remained in situ was 48hours. Drain was effective in 100% of the cases. Apart from a case of drain dislodgement, there was no other complication.

CONCLUSION: The syringes can be an effective closed suction drain in rural surgical practice.

3.
SALVAGING AN ISCHAEMIC LOWER LIMB- A CASE REPORT

Esezobor EE, Onuminya j E

Department of Surgery and Orthopedics. Irrua Specialist Teaching Hospital, Irrua Edo State.

BACKGROUND: Chronic leg ulcer from arterial insufficiency can be a nightmare for any plastic surgeon working in rural sub-Saharan Africa. Most patients will have to consent to amputation either due to the pain or lack of facilities to intervene. This case report highlight the challenges involved in salvaging an arterial leg ulcer

CASE REPORT: This is a 75 year old hypertensive woman who presented with ulcer on the right leg of 3 week duration and positive history of intermittent claudication. Investigation supported the diagnosis of arterial insufficiency. Patient had balloon angioplasty and wound care. The ulcer healed and the patient discharged pain free with improved claudication distance