

www.ajbrui.org

Afr. J. Biomed. Res. Vol. 26 (May 2023); 281- 289

Research article

Glycine Exerts Renal Antioxidant Effects and Restores Hemodynamic Alterations in Rats Treated with Diclofenac Sodium: Roles of Renal Angiotensin Converting Enzyme, Angiotensin II Receptor and Mineralocorticoid Receptor

Akinrinde A.S.^a, Ajibade T.O.^{a*}, Adetona M.O.^b Oyagbemi A.A.^a, Adedapo A.D.A.^c, Larbie C.^d, Omobowale^e T.O., Ola-Davies O.E.^a, Adedapo A.A.^f, Saba A.B.^f, Oguntibeju O.O.^g, Yakubu M.A.^h

Departments of ^aVeterinary Physiology and Biochemistry, ^bAnatomy, ^cPharmacology and Therapeutics, ^eVeterinary Medicine and ^fVeterinary Pharmacology and Toxicology, University of Ibadan, Ibadan, Nigeria.

^dDepartment of Biochemistry and Biotechnology, College of Science, Kwame Nkrumah University of Science and Technology, Kumasi, Ghana.

^gPhytomedicine and Phytochemistry Group, Oxidative Stress Research Centre, Department of Biomedical Sciences, Faculty of Health and Wellness Sciences, Cape Peninsula University of Technology, Bellville 7535, South Africa

^hDepartment of Environmental & Interdisciplinary Sciences, College of Science, Engineering & Technology, Vascular Biology Unit, Center for Cardiovascular Diseases, Texas Southern University, Houston, TX, USA.

ABSTRACT

Diclofenac (DIC) is known to alter renal function in the form of hemodynamically-mediated acute renal failure. This study evaluated the protective role of the amino acid, glycine (Gly) on nephrotoxicity and acute hemodynamic alterations induced by DIC (9 mg/kg) in male Wistar rats. The rats were divided into four groups (n=7/group) including Group A (control); Group B (DIC-treated), Groups C (DIC + Gly1, 250 mg/kg) and Group D (DIC + Gly2 500 mg/kg). Systolic (SBP), diastolic (DBP) and mean arterial (MAP) blood pressures were significantly (p<0.05) reduced in rats treated with DIC alone, compared to control. Kidneys from DIC-treated rats showed altered histology with significantly (p<0.05) increased hydrogen peroxide (H₂O₂), malondialdehyde (MDA) and protein carbonyl contents, but decreased glutathione (GSH) glutathione peroxidase (GPx), glutathione S-transferase (GST) and superoxide dismutase (SOD) activities. Immunohistochemistry revealed down-regulation of renal angiotensin converting enzyme (ACE), but increased expressions of angiotensin type II receptor (AT₂R) and mineralocorticoid receptor (MR) in DIC-treated rats. However, pre-treatment with Gly reversed most of the aforementioned effects of DIC. The present results suggest that oral glycine protected kidney tissues and restored DIC-induced hemodynamic changes by modifying renal expression of the renin-angiotensin-mineralocorticoid pathway and/or renal oxidative stress.

Keywords: *Kidneys, Diclofenac, Glycine, immunohistochemistry, receptors, blood pressure*

*Author for correspondence: Email: to.ajibade@ui.edu.ng; Tel: +234 (0) 9071842142

Received: November 2022; Accepted: March 2023

DOI: 10.4314/ajbr.v26i2.18

INTRODUCTION

Non-steroidal anti-inflammatory drugs (NSAIDs) are among the most widely used drugs globally, with Diclofenac (DIC) being one of the most frequently prescribed for general management of pain and inflammation in a variety of conditions in human and veterinary practice (Gomaa, 2018). However, these drugs are associated with a number of untoward clinical events, most notably involving the gastrointestinal tract and kidneys. Among other potential mechanisms, the pharmacological and toxicological actions of

NSAIDs arise from their ability to inhibit cyclooxygenase (COX) enzymes, including COX-1 and COX-2, with consequent reduction in prostaglandin synthesis (Zerbini et al., 2011).

The kidneys, among other functions, are involved in the elimination of toxic products and drug metabolites as well as the maintenance of blood pressure (Simon and Evan Prince, 2018). Local injury to renal tissues due to drugs or other toxic substances may result in a compromise of these functions. Kidney injury due to NSAIDs has been attributed to changes

in renal hemodynamics, characterized by vasoconstriction of renal vessels and reduced blood flow to the kidneys, as a result of inhibition of prostaglandins that would otherwise mediate vasodilation (Patzner, 2008). However, the nephrotoxic effects of NSAIDs are often obscure due to a lack of clinical symptoms, although acute kidney injury due to the use of NSAIDs is now increasingly recognized with systematic blood tests in patients even without pre-existing renal disease (Perazella, 2014). Renal lesions, such as ischemia and acute tubular necrosis have also been described mostly in patients with accompanying volume depletion (hypovolemia) (Clave et al., 2019)

Renal regulation of blood pressure usually involves the activation of the renin-angiotensin-aldosterone system (RAAS), which along with the associated receptors is responsible for maintenance of volume and electrolyte homeostasis (Samuel et al., 2018). A drop in blood volume or blood pressure stimulate specialized cells called macula densa in the distal tubules and the juxtaglomerular apparatus to secrete the enzyme renin, which generates angiotensin I after cleavage of a protein precursor called angiotensinogen. Angiotensin converting enzyme (ACE) derived from the lungs then catalyzes the conversion of angiotensin I to angiotensin II (Hani and Stephen, 2012). Ang II mediates increase in blood pressure by regulating vascular smooth muscles via its interaction with angiotensin receptors, Type 1 (AT1R) and Type 2 (AT2R) (Henrion et al., 2001). The binding of Ang II to AT1R is believed to cause vasoconstriction and inhibition of natriuresis via stimulation of aldosterone secretion from the adrenal cortex, which subsequently interacts and mineralocorticoid receptor (MR) to promote renal salt retention. On the other hand, studies have demonstrated that AT2R is responsible for vasodilatory activities and natriuresis, seemingly opposing the actions of AT1R, and as such, providing a protective role in hemodynamic regulation and sodium excretion (Carey, 2000).

Cellular oxidative stress resulting either from an overproduction of reactive oxygen species (ROS) or a suppression of antioxidant mechanisms is an important contributor to DIC-induced *in vivo* toxicity to different tissues, including the kidneys (Simon and Evan Prince, 2018; Alabi et al., 2017). Major sources of ROS generation during DIC intoxication include disturbances with mitochondrial oxidative phosphorylation and ATP generation, as well as via NADPH oxidase (NOX)-dependent mechanisms (Li et al., 2008; Syed et al., 2016), both of which contribute to increased production of radical superoxide anion and other free radicals. From the foregoing, we hypothesized that agents combining antioxidant activity with an ability to modulate renal regulation of blood pressure could have significant clinical impact in ameliorating drug-induced renal toxicity and hemodynamic changes.

Glycine (Gly), an amino acid component of several cellular proteins has been shown to protect cellular oxidative stress caused by a variety of xenobiotics (Shafiekhani et al., 2019). Its antioxidant activity is mainly connected to its involvement in the synthesis of reduced glutathione (GSH), a vital cellular antioxidant defense (Senthikumar et al., 2004; Heidari et al., 2018). Reduced glutathione, consisting of the amino acids Gly, cysteine and glutamate, is synthesized in two

reactions catalyzed by the enzymes, glutamyl cysteine synthetase and GSH synthetase (Wu et al., 2002), with Gly being a limiting factor for the synthetic process. As an antioxidant GSH can either function by direct scavenging of free radicals or it could be utilized indirectly as a co-factor for glutathione peroxidase (GPx) (Lei, 2002). Gly has been reported to possess nephroprotective activities through an inhibition of oxidative stress (Shafiekhani et al., 2019), while some studies also provide evidence of its ability to provide beneficial effects on blood pressure regulation (El-Hafidi et al., 2006).

Reports on the effects of DIC on BP in humans are far from unanimous, while studies in experimental animals are also inconclusive with some reports suggesting its ability to raise blood pressure (Izhar et al., 2004), while some other studies have found no significant BP changes following DIC administration (Sherve et al., 2014). The central role of the kidneys in the regulation of arterial pressure (Wadei and Textor, 2012) suggests that the kidneys may play an important role in hemodynamic changes associated with DIC treatment. Herein, we sought to investigate the modulatory effects of Gly on nephrotoxicity and hemodynamic changes induced by DIC in rats as well as the mechanistic involvements of some critical components of the RAAS, including ACE, AT2R and MR.

MATERIALS AND METHODS

Chemicals: Diclofenac sodium (Voltaren®) was purchased from a reputable pharmacy in Ibadan, Nigeria. Glycine, Xylenol orange, sodium hydroxide, reduced glutathione (GSH), adrenaline, 5, 5'-dithio-bis-2-nitrobenzoic acid (DTNB), 1, 2-dichloro-4-nitrobenzene (CDNB), thiobarbituric acid (TBA), trichloroacetic acid (TCA) and other reagents were products from Sigma-Aldrich (St. Louis, MO, USA). Anti-Angiotensin Converting Enzyme (ACE), anti-Angiotensin II receptor (AT₂R) and anti-Mineralocorticoid receptor (MR) antibodies were procured from Bioss Inc. (Woburn, MA, USA). Diaminobenzidine (DAB) was purchased from AMRESCO LLC. (OH, USA). Biotinylated antibody, normal goat serum and Horse Radish Peroxidase (HRP) System were purchased from KPL, Inc. (Gaithersburg, MD). All other chemicals used were of analytical grade.

Animals and experimental design: Twenty eight male Wistar albino rats were obtained from the Experimental Animal Unit of the University of Ibadan, Nigeria. They were initially allowed a 7-day acclimatization period with food and water *ad libitum*. The experimental protocol was guided by the criteria outlined in the "Guide for the Care and Use of Laboratory Animals" (PHS, 1996), published by the National Institute of Health. The study was approved by the local ethics committee, the Animal Care Use and Research Ethics Committee (ACUREC) of the University of Ibadan, Nigeria. The rats were randomly assigned to four groups containing seven rats each as follows: Control group, where rats received physiological saline daily for 8 days; DIC group, in which rats were exposed orally to DIC at 9 mg kg⁻¹ b. w. administered twice daily on days 6-8 (Singh *et al.*, 2017; Akinrinde *et al.*, 2020); DIC + Gly₁ group, where rats received Gly at 250 mg kg⁻¹ b. w. for 8 days along with DIC for the last three days

(days 6-8) and DIC + Gly₂ group, in which rats were treated with Gly at 500 mg kg⁻¹ b. w. for 8 days along with DIC on days 6-8. The dosage of Gly was chosen based on effects observed with its use in previous reports (Shafiekhani *et al.*, 2019; Li *et al.*, 1995; Akinrinde *et al.*, 2021).

Blood pressure measurement: Blood pressure indices (SBP, DBP and MAP) and the heart rates of the rats were measured by means of the CODA high throughput BP system (CODA, Kent Scientific, USA). An average of at least nine readings per animal was taken indirectly via tail plethysmography with the electrospigmomanometer. Prior to the measurements, rats were initially acclimatized to the sphygmomanometer conditions by brief placement in the provided animal nose cone holder in the two days before the actual measurements.

Necropsy and preparation of samples: The animals were euthanized by cervical dislocation following xylazine/ketamine anaesthesia 24 hours after the last dosing with DIC and Gly. The abdomen was opened and the kidneys were removed, rinsed in ice-cold saline. The tissues were homogenized in appropriate homogenizing buffer and the homogenates were thereafter centrifuged at 10,000×g for 10 min in a refrigerated centrifuge (4 °C). The supernatant was then collected for biochemical analyses. Separate kidney tissues were collected in 10% phosphate buffered formalin ahead of their processing for histopathological examination.

Biochemical Analysis: The homogenized samples were used to estimate oxidative stress and antioxidant markers by means of standard spectrophotometric assay protocols. Renal hydrogen peroxide (H₂O₂) generation was measured at 560 nm according to the method of Wolff (Wolff, 1994). The level of lipid peroxidation was estimated by measuring tissue levels of malondialdehyde (MDA), with a molar extinction coefficient of 1.56 X 10⁵ M⁻¹cm⁻¹ according to methods described by Varshney and Kale (Varshney and Kale, 1990). Protein carbonyl concentration in the samples was measured using the method of Reznick and Packer (Reznick and Packer, 1994). The activities of glutathione peroxidase (GPx) and glutathione S-transferase (GST) were determined based on the methods described by Rotruck *et al.* (Rotruck *et al.*, 1973) and Habig (Habig and Pabst, 1974) respectively. Superoxide dismutase (SOD) activity was estimated by a method utilizing the inhibition of the auto-oxidation of epinephrine in an acidified medium according to the method of Misra and Fridovich (Misra and Fridovich, 1972). Total protein concentration was determined by the method of Gornal *et al.* (Gornal *et al.*, 1949). The renal GSH concentration was determined by the method of Beutler *et al.* (Beutler *et al.*, 1963), while protein thiols and non-protein thiol contents (Ellman, 1959) were measured by respective standard assays.

Histopathological examination: Renal tissues kept in formalin were processed using standard histological techniques ((Drury and Wallington, 1976), including dehydration in ascending dilutions of alcohol and embedding in paraffin. The tissues were embedded in paraffin and sections 5-6 μm thick were prepared, mounted on plain glass slides and then stained with Hematoxylin and eosin (H&E).

Immunohistochemistry: Immunohistochemical staining of kidney sections was carried out to demonstrate the expression of Angiotensin Converting Enzyme (ACE), Angiotensin type II receptor (AT₂R) and Mineralocorticoid receptor (MR) according to methods described by Todorich *et al.* (2011). In summary, the sections were first deparaffinized in an oven at about 60°C followed by dewaxing with xylene. They were then rehydrated by washing in a series of graded ethanol solutions of decreasing concentrations. A 1% solution of hydrogen peroxide in methanol was used in peroxidase quenching, while antigen epitopes were retrieved by immersing the slides in citrate buffer along with heating in a microwave oven. The slides were blocked in 10% normal goat serum for 1h at room temperature (25°C). Thereafter, the slides were incubated overnight at room temperature with primary antibodies. For bound antibody detection, the slides were exposed to biotinylated goat anti-rabbit secondary antibody, followed by a streptavidin-peroxidase conjugate (HistoMark® Gaithersburg MD). The product of the reaction was treated with the substrate, diaminobenzidine and counter-stained with hematoxylin. Following alcohol dehydration, the slides were viewed with a light microscope to observe the immunoreactive regions.

Statistical Analysis: Data were subjected to analysis using one way analysis of analysis of Variance (ANOVA). Tukey's *post hoc* analysis was conducted for multiple comparisons. The data have been presented as mean ± standard deviation and p-values <0.05 were considered statistically significant.

RESULTS

Blood pressure and heart rate recordings: Values of SBP, DBP and MAP were significantly (p<0.05) lowered following three days of oral DIC treatment compared with the control group. Rats in the DIC + Gly₁ and DIC + Gly₂, however, witnessed an increase in SBP and MAP compared to the DIC group, representing a restoration back to control values (Fig. 1A, B, C), as DBP remained lower than control values in these groups. Meanwhile, the heart rates in the rats did not differ significantly across all the groups (Fig. 1D).

Renal markers of oxidative stress and antioxidant status: Renal H₂O₂, MDA and protein carbonyl levels were significantly (p<0.05) elevated in DIC-treated group compared to the control group (Fig. 2A, B, C). Treatment with Gly, however, prevented the elevation in oxidative markers as it caused significant (p<0.05) reduction in H₂O₂, MDA and protein carbonyl levels relative to the DIC group. Also, the higher dose, Gly₂ produced better amelioration of oxidative stress compared to the lower dose, Gly₁. Moreover, oral administration of DIC induced a remarkable (p<0.05) decrease in renal levels of reduced glutathione (GSH) and protein thiols (Fig. 3A, B), when compared to the control group without significantly affecting levels of non-protein thiols (Fig. 3C). Treatment with Gly, especially at the higher dose, resulted in significant (p<0.05) improvement of GSH and non-protein thiol levels, compared with the DIC group, while protein thiol levels remained low as obtained with the DIC group. Also, the higher dose, Gly₂ produced better amelioration of oxidative stress compared to the lower dose, Gly₁.

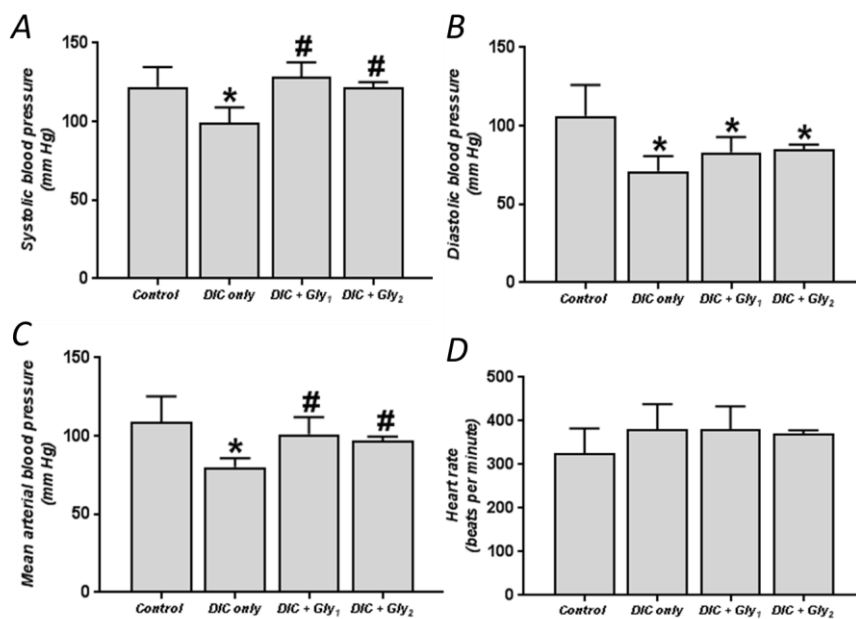


Figure 1: Systolic (A), diastolic (B), Mean arterial (C) pressures and heart rate (D) of male Wistar rats treated orally with Glycine (250 and 500 mg/kg once daily) and Diclofenac (9 mg/kg b. w. twice daily). Data are expressed as mean±standard deviation (n = 7). * indicates significant difference ($p < 0.05$) compared to the control group; # indicates significant difference ($p < 0.05$) compared to the DIC group. DIC, Diclofenac; Gly, Glycine

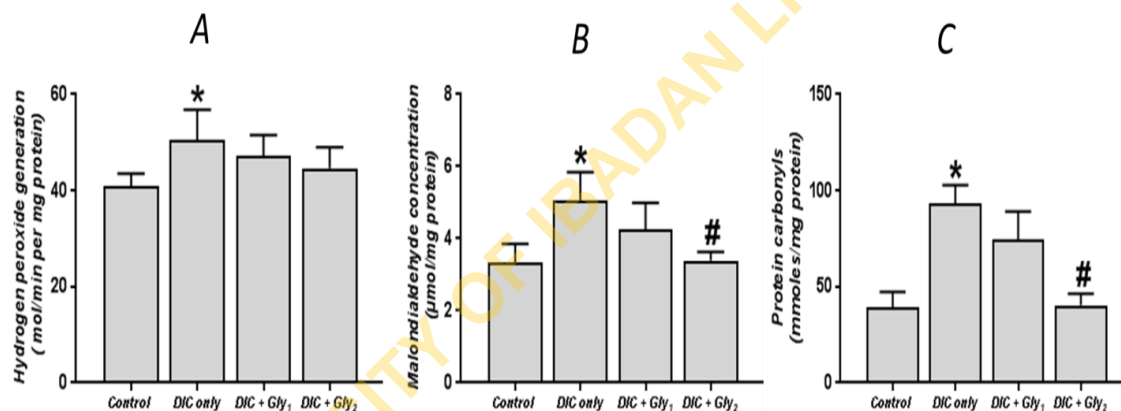


Figure 2: Hydrogen peroxide (A), malondialdehyde (B) and protein carbonyl (C) levels in male Wistar rats treated orally with Glycine (250 and 500 mg/kg once daily) and Diclofenac (9 mg/kg b. w. twice daily). Data are expressed as mean±standard deviation (n = 7). * indicates significant difference ($p < 0.05$) compared to the control group; # indicates significant difference ($p < 0.05$) compared to the DIC group. DIC, Diclofenac; Gly, Glycine

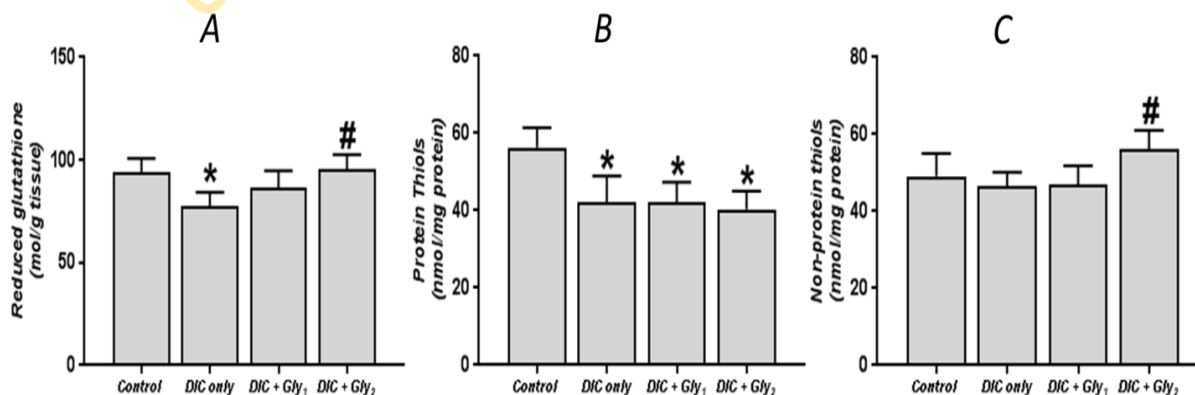


Figure 3: Reduced glutathione (A), protein thiol (B) and non-protein thiol (C) levels in male Wistar rats treated orally with Glycine (250 and 500 mg/kg once daily) and Diclofenac (9 mg/kg b. w. twice daily). Data are expressed as mean±standard deviation (n = 7). * indicates significant difference ($p < 0.05$) compared to the control group; # indicates significant difference ($p < 0.05$) compared to the DIC group. DIC, Diclofenac; Gly, Glycine

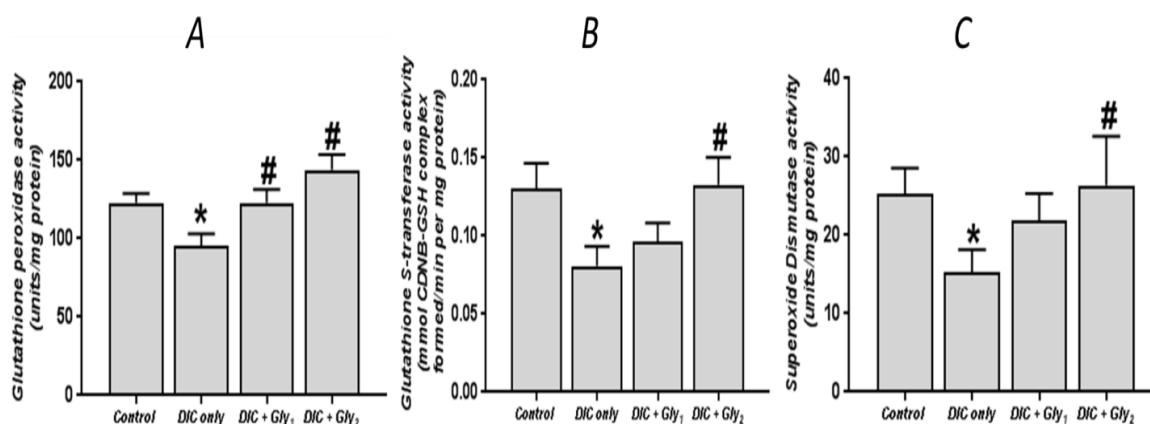


Figure 4:

Glutathione peroxidase (GPx) (A), glutathione S-transferase (GST) (B) and superoxide dismutase (SOD) (C) activities in male Wistar rats treated orally with Glycine (250 and 500 mg/kg once daily) and Diclofenac (9 mg/kg b. w. twice daily). Data are expressed as mean \pm standard deviation (n = 7). * indicates significant difference (p<0.05) compared to the control group; # indicates significant difference (p<0.05) compared to the DIC group. DIC, Diclofenac; Gly, Glycine.

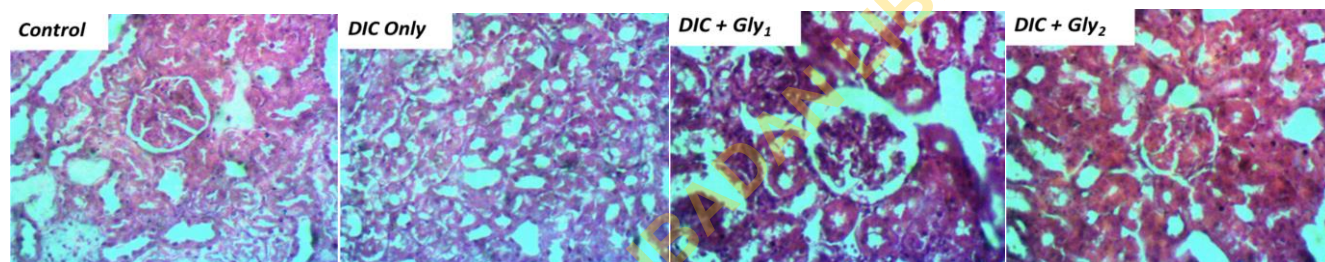


Plate 1

Photomicrographs of renal tissues (stained with H&E; x400). Control group showed normal glomerulus and renal tubules. DIC group showed multifocal tubular coagulation necrosis. DIC + Gly₁ and DIC + Gly₂ groups showed normal glomeruli and renal tubules with no observable lesions.

Furthermore, DIC treatment caused significant (p<0.05) reduction in the renal activities of glutathione peroxidase (GPx), glutathione S-transferase (GST) and superoxide dismutase compared with the control group (Fig. 4A, B, C). Again, there was significant (p<0.05) increase in the activities of these enzymes following Gly treatment, which is further evidence of the antioxidant activities of Gly in the kidneys.

Renal histopathology: Control and Gly-treated rats showed normal glomeruli and normal morphology of renal tubules (Plate 1A, C, D). In contrast, the kidney sections from DIC-treated rats showed multifocal necrosis of kidney tubules and indistinct morphology of glomeruli (Plate 1B). The morphology of the kidney sections in the Gly-treated rats points to remarkable amelioration of histopathological alterations observed in the DIC group.

Immuno-histochemical findings

Angiotensin Converting Enzyme: Immuno-histochemical investigation revealed mild ACE staining in the control group, while the DIC group showed lower ACE immuno-staining

reaction, compared to the control group. However, rats treated with Gly showed strong positive ACE immune staining which was higher in the rats given the higher dose of Gly (Plate 2). Increased ACE immunostaining in Gly-treated rats appeared to be in response to the lowered blood pressure in DIC-treated rats.

Angiotensin type II receptor: Immunohistochemistry revealed negative AT₂R immunostaining reaction in renal tissues of control rats (Plate 3). On the other hand, the rats treated with DIC only exhibited relatively stronger renal AT₂R immunostaining compared to the control and a similar trend was shown by rats in the DIC + Gly₁ group. However, rats in the DIC + Gly₂ group showed reduction in immune reactivity of AT₂R, compared to the DIC group (Plate 3).

Mineralocorticoid receptor: Immunohistochemical staining of the mineralocorticoid receptor in renal tissues are presented in Fig. 8. There was weak expression of MR in the control rats. In contrast, higher expression levels of MR were observed in rats of the DIC, DIC + Gly₁ and DIC + Gly₂ groups.

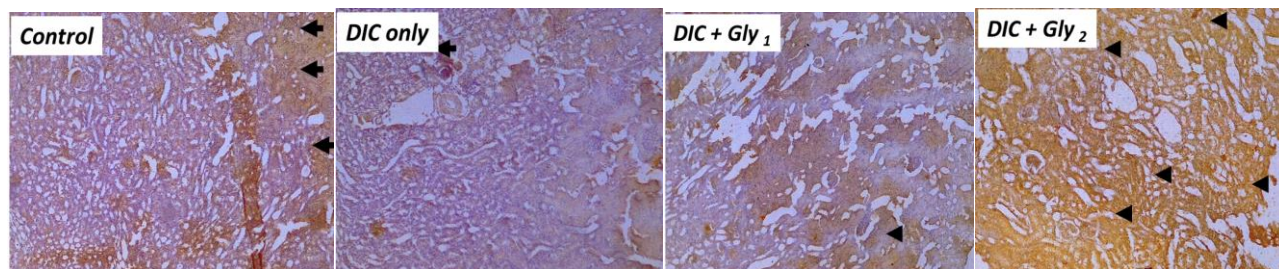


Plate 2

Immunohistochemical staining of angiotensin converting enzyme (ACE) in rat kidney. Control rats showed low expression of ACE; DIC group showed much lower expression of ACE when compared to the control; DIC + Gly₁ (250 mg/kg) group showed higher expression of ACE when compared to DIC group; DIC + Gly₂ (500 mg/kg) group showed strong positive staining of ACE when compared to the DIC group. Regions of ACE immunoreaction are shown as brown-colored areas indicated by black arrows. Slides were stained with high definition *Haematoxylin*. Magnification: x 100.

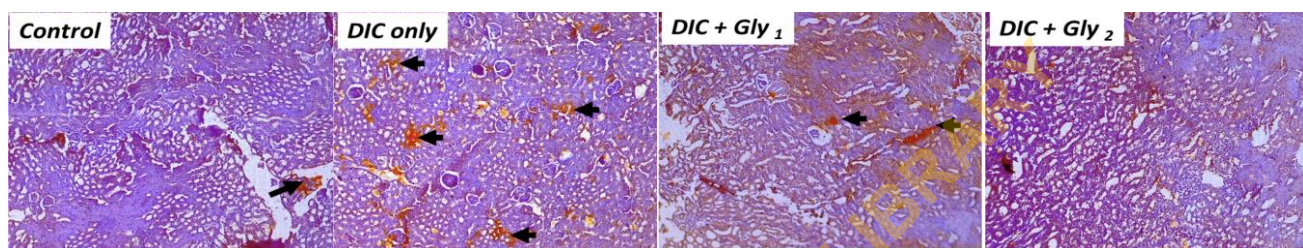


Plate 3:

Immuno-histochemical staining of angiotensin II (AT₂R) in rat kidney. Control rats showed low expression of AT₂R; DIC group showed relatively increased expression of AT₂R when compared to the control; DIC + Gly₁ (250 mg/kg) group showed lower expression of AT₂R when compared to DIC group; DIC + Gly₂ (500 mg/kg) group showed weak AT₂R staining when compared to the DIC group. Regions of AT₂R immunoreaction are shown as brown-colored areas indicated by black arrows. Slides were stained with high definition *Haematoxylin*. Magnification: x 100.

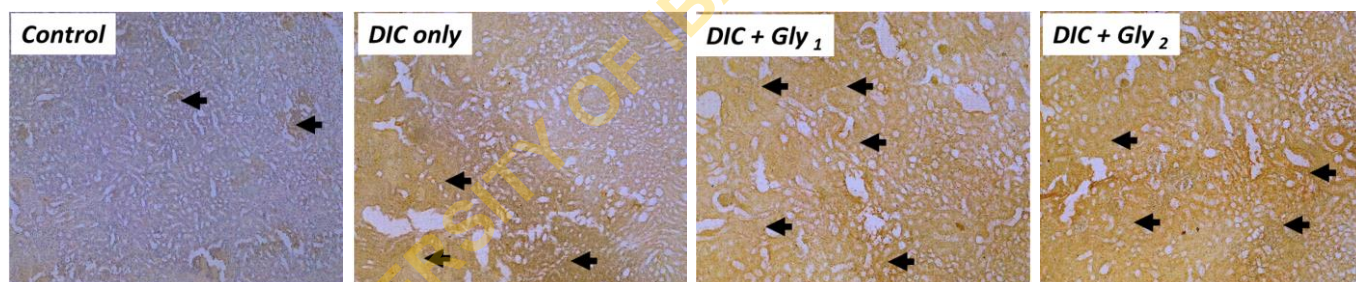


Plate 4:

Immuno-histochemical staining of mineralocorticoid receptor (MR) in rat kidney. Control rats showed low expression of MR; DIC group showed relatively increased expression of MR when compared to the control; DIC + Gly₁ (250 mg/kg) group also showed increased expression of MR similar to the DIC group; DIC + Gly₂ (500 mg/kg) group also showed strong positive MR staining also comparable to the DIC group. Regions of MR immunoreaction are shown as brown-colored areas indicated by black arrows. Slides were stained with high definition *Haematoxylin*. Magnification: x 100

DISCUSSION

The current report revealed an interesting finding indicating that DIC administered twice daily to rats for three days can precipitate acute hemodynamic changes in rats that reflect a lowering of BP (systolic, diastolic and mean arterial pressure). Reports in scientific literature suggest that there is no unified hemodynamic/blood pressure response to administration of COX inhibitors (selective and non-selective) (Johnson, 1997; Snowden and Nelson, 2011). What appears certain from most reports, however, is that most NSAIDs interfere with the regulation of blood pressure. Traditional NSAIDs e.g. ibuprofen and naproxen have been associated with a tendency to increase BP, especially in patients with pre-existing hypertensive dispositions (Ruschitzka et al., 2017). The effect has been attributed to their inhibition of prostaglandin

synthesis, anti-natriuretic and vasoconstrictor actions (Izhar et al., 2004). Other reports have suggested that some of these drugs, such as DIC and aspirin do not have any effect on BP (Sherve et al., 2014).

The reported differential effects of NSAIDs on BP have been attributed to discrepancies in pharmacokinetics between the different drugs and differences in the dosages used as well as the frequency of dosing (Stempak et al., 2002). For instance, to achieve pain relief in humans, DIC is often administered twice daily while celecoxib is used once daily. In addition, significant gastrointestinal side effects and a tendency for these drugs to reduce renal perfusion may complicate hemodynamics when they are used. In the present study, DIC-treated rats presented with severe dark watery diarrhea (data not shown), as reported in previous studies (Akinrinde et al., 2020). We opine that significant acute losses of fluid via the gastrointestinal tract and probable contraction

of blood volume (hypovolemia) and/or reduced renal perfusion might contribute to the lowered BP observed in DIC-treated rats (Patzer, 2008).

In line with the lowering of BP in DIC-treated rats, immuno-histochemical examination of renal tissues indicated a reduction in ACE expression compared to control rats, which appeared to correlate with the DIC-induced reduction in blood pressure, probably due to a corresponding reduction in downstream molecules of the RAAS pathway, including angiotensin II or aldosterone. ACE normally converts Ang I to Ang II, which then binds to AT1R to increase secretion of aldosterone (Hani and Stephen, 2012). Although Ang II expression was not examined in the present study, we found evidence of increased expression of receptors for both AT2R and MR, suggesting a physiological compensatory response of renal tissues to counteract the reduction in BP by DIC. In support of our findings, previous work has demonstrated novel functions of AT2R which appears to oppose the vasoconstrictor and anti-natriuretic effects AT1R, rather causing vasodilation and natriuresis by stimulating autocrine secretion of mediators such as bradykinin, nitric oxide and cGMP (Carey, 2000). Although the expression of AT2R mRNA is known to be limited in most adult tissues, Ozono et al. (Ozono et al., 1997) reported that the receptor protein can be detected by immunohistochemistry or Western blotting, as obtained in the present study. It seems, therefore, that drugs such as DIC may possess counter-regulatory effects to the effects of binding of angiotensin II to AT1R.

In this study, rats treated with Gly exhibited a partial reversal of BP changes induced by DIC reflected in increases in systolic and mean arterial pressure to values similar to those of control rats. The mechanisms involved in this reversal of BP changes may be associated with the induction of renal ACE and/or MR expression by Gly as obtained in the present study. In support of our findings, Li et al. (1995) reported that Gly at a dose of 0.5 or 1.0 g/kg produced marked attenuation of cisplatin-induced nephrotoxicity and also restored hemodynamic changes, via its ability to prevent cisplatin-induced reduction in renal blood flow and glomerular filtration rate. In an experimental model of hypertension, the mechanisms of the protective effects of Gly on nephrotoxicity and BP was attributed to its contribution to the reduction of the free radical generation, as well as its ability to modulate aorta's elastic properties due to its involvement in the synthesis of collagen and elastin (El-hafidi et al., 2004; 2006).

Antioxidants play critical roles in protection of cells from reactive oxygen species (ROS) mediated oxidative injury. The present results showed evidence of renal oxidative stress and nephrotoxicity indicated by significantly elevated levels of H₂O₂, MDA and protein carbonyls with lower GSH levels and reduced activities of GPx, GST and SOD in DIC-treated rats compared to the control rats. Similar to our findings, Famurewa et al. (2020) also reported that DIC administered intraperitoneally at 100 mg/kg for three days produced marked elevation in renal MDA levels and reduced renal activities of catalase (CAT), GPx and SOD. Our results showed that oral administration of Gly significantly ameliorated the DIC-induced oxidative damage by lowering the levels of H₂O₂, MDA and protein carbonyls and producing significant enhancement of the activities of the antioxidant enzymes. We

found that the higher dose of Gly used in this study consistently produced better improvement of the oxidative status of the renal tissues.

By employing different antioxidant mechanisms, Gly can prevent ROS formation or minimize the impairment of the activity of antioxidant enzymes and as such, show beneficial effect against several conditions associated with increased generation of free radicals (Ruiz-Mena et al., 2004). Being a limiting factor for GSH synthesis, Gly and GSH deficiency contributes to oxidative stress and, therefore, may play a key role in the pathogenesis of hypertension. Wang et al. (Wang et al., 2018) had earlier suggested that Gly protected renal tissues against oxidative stress by enhancing GSH synthesis and suppressing NADPH oxidase expression in diabetic rats.

The histopathological assessment of kidney tissues obtained from DIC-treated rats emphasized our findings of nephrotoxicity in this group. While the renal architecture of control rats showed normal morphology of glomeruli and renal tubules, the sections from DIC-treated rats had distorted morphology showing indistinct glomeruli and multifocal tubular coagulation necrosis. In support of these histological findings, Alabi et al. (Alabi et al., 2018) also recorded profound acute tubular necrosis in rats treated with 10 mg/kg DIC for 7 days. Rats treated with Gly showed considerable preservation of renal morphology with no obvious lesions observed. The observed protection of renal tissues is in agreement with findings of Shafiekhani et al. (2019) who reported that Gly at 500 and 1000 mg/kg ameliorated histopathological changes induced by lead acetate, including tubular dilation, protein cast, vacuolization, and inflammation.

In conclusion, this study revealed that acute DIC administration can precipitate reduction in systolic, diastolic and mean arterial pressures, and at the same time induce oxidative stress in the kidneys of rats. Moreover, the study demonstrated that DIC-induced hypotension may be related to a reduced renal ACE expression, accompanied by increased expression of AT2R and MR. The latter changes may be physiological compensatory responses to counteract the reduced BP. Treatment of rats with Gly produced partial reversal of the DIC-induced BP changes and this was notably reflected in the respective tissue expressions of ACE and MR. The administration of Gly resulted in preservation of renal morphology and this could be attributed to its antioxidant activity and inhibition of oxidative processes. Taken together, Gly supplementation showed considerable promise for the prevention and/or management of drug-induced nephrotoxicity and hemodynamic alterations.

REFERENCES

- Akinrinde A.S., Soetan K.O., Tijani M.O. (2020):** Exacerbation of diclofenac-induced gastroenterohepatic damage by concomitant exposure to sodium fluoride in rats: protective role of luteolin, *Drug Chem. Toxicol.*, DOI: 10.1080/01480545.2020.1802478
- Akinrinde A.S., Hameed H.O. (2021):** Glycine and L-Arginine supplementation ameliorates gastro-duodenal toxicity in a rat model of NSAID (Diclofenac)-gastroenteropathy via inhibition of oxidative stress. *J Basic Clin Physiol Pharmacol.* 33(3), 285-295. doi: 10.1515/jbcpp-2020-0307.

- Alabi Q.K., Akomolafe R.O., Olukiran O.S., Adeyemi W.J., Nafiu A.O., Adefisayo M.A., Omole J.G., Kajewole D.I., Odujoko O.O. (2017):** The *Garcinia kola* biflavonoid, kolaviron attenuates experimental hepatotoxicity induced by diclofenac. *Pathophysiology*. 24(4), 281-290.
- Alabi Q.K., Akomolafe R.O., Adefisayo M.A., Olukiran O.S., Nafiu A.O., Fasanya M.K., Oladele A.A. (2018):** Kolaviron attenuates diclofenac-induced nephrotoxicity in male Wistar rats. *Appl Physiol Nutr Metab*. 43(9), 956-968.
- Beutler E.O., Duron B., Kelly M. (1963):** Improved method for the determination of blood glutathione. *J. Lab. Clin. Med.* 61, 882-888.
- Carey R.M., Wang Z.-Q., Siragy H.M. (2000):** Role of the Angiotensin Type 2 Receptor in the Regulation of Blood Pressure and Renal Function. *Hypertension*. 35, 155-163
- Clave S., Rousset-Rouviere C., Daniel L., Tsimaratos M. (2019):** The invisible threat of Cyclooxygenase inhibitors for kidneys. *Front. Pediatr.* <https://doi.org/10.3389/fped.2019.00520>
- Drury R.A., Wallington E.A. (1976): *Carlton's Histopathological Techniques*, 4th ed. Oxford University Press, London, pp. 139-142.
- El Hafidi M., Pe' rez I., Zamora J., et al. (2004):** Glycine intake decreases plasma free fatty acids, adipose cell size, and BP in sucrose-fed rats. *Am. J. Physiol.* 287, R1387-R1393.
- El Hafidi M., Pérez I., Baños G. (2006):** Is glycine effective against elevated blood pressure? *Curr. Opin. Clin. Nutr. Metab. Care*. 9(1), 26-31. doi: 10.1097/01.mco.0000196143.72985.9a.
- Ellman, G.L. (1959).** Tissue sulfhydryl groups. *Archives of Biochemistry and Biophysics*, 82 (1), 70-77.
- Famurewa A.C., Akunna G.G., Nwafor J., Chukwu O.C., Ekeleme-Egedigwe C.A., Oluniran J.N. (2020):** Nephroprotective activity of virgin coconut oil on diclofenac-induced oxidative nephrotoxicity is associated with antioxidant and anti-inflammatory effects in rats. *Avicenna J Phytomed*. 10(3), 316-324.
- Gomaa S. (2018):** Adverse effects induced by diclofenac, ibuprofen, and paracetamol toxicity on immunological and biochemical parameters in Swiss albino mice. *JoBAZ* 79, 5.
- Gornal A.G., Bardawill J.C., David M.M. (1949):** Determination of serum proteins by means of Biuret reaction. *J. Biol. Chem.* 177, 751-766.
- Habig W.H., Pabst M.J. (1974):** Glutathione-S-transferases. The first enzymatic step in mercapturic acid formation. *J. Biol. Chem.* 25, 7130-7139
- Hani M.W., Stephen C.T. (2012):** The role of the kidney in regulating arterial blood pressure. *Nat. Revs. Nephrol.* 8, 602-609.
- Heidari R., Mohammadi H., Ahmadi A.A., et al. (2018):** Protective effect of glycine and tri-methyl glycine (betaine) against heavy metals-induced oxidative stress in liver-derived post-nuclear supernatant (PNS). *Trends Pharm Sci.* 4(2), 113-124.
- Henrion D., Kubis N., Lévy B.I. (2001)** Physiological and pathophysiological functions of the AT(2) subtype receptor of angiotensin II: from large arteries to the microcirculation. *Hypertension*, 38(5), 1150-7. doi: 10.1161/hy1101.096109.
- Izhar M., Alausa T., Folker A., Hung E., Bakris G.L. (2004):** Effects of COX Inhibition on Blood Pressure and Kidney Function in ACE Inhibitor-Treated Blacks and Hispanics. *Hypertension*. 43, 573-577
- Johnson A.G. (1997):** Coxibs and increased blood pressure. What is the clinical significance? *Drug Saf.* 17(5), 277-289.
- Lei X.G. (2002).** *In vivo* antioxidant role of glutathione peroxidase: evidence from knockout mice. *Methods Enzymol*. 347, 213-225.
- Li Q., Bowmer C.J., Yates M.S. (1995):** Amelioration of Cisplatin Nephrotoxicity with Glycine: Dose Dependency in Rats. *J. Pharm. Pharmacol.* 47(3), 223-226. <https://doi.org/10.1111/j.2042-7158.1995.tb05783.x>
- Li H., Hortmann M., Daiber M., et al. (2008):** Cyclooxygenase 2-selective and nonselective nonsteroidal anti-inflammatory drugs induce oxidative stress by up-regulating vascular NADPH oxidases. *J. Pharmacol. Exp Therap.* 326 (3), 745-753.
- Misra H.P., Fridovich I. (1972):** The role of superoxide anion in the autoxidation of epinephrine and a simple assay for superoxide dismutase. *J. Biol. Chem.* 247, 3170-3175.
- Ozono R., Wang Z.Q., Moore A.F., Inagami T., Siragy H.M., Carey R.M. (1997)** Expression of the subtype 2 angiotensin (AT2) receptor protein in rat kidney. *Hypertension*, 1997, 30(5):1238-46. doi: 10.1161/01.hyp.30.5.1238.
- Patzer I. (2008):** Nephrotoxicity as a cause of acute kidney injury in children. *Pediat. Nephrol.* 23, 2159-2173.
- Perazella M.A. (2014):** Diagnosing drug drug-induced AIN in the hospitalized patient: a challenge for the clinician. *Clin. Nephrol.* 81, 381-388.
- Public Health Service (PHS).(1996):** Public health service policy on humane care and the use of laboratory animals. Washington, DC: US Department of Health and Humane Services, 99-158.
- Reznick A.Z., Packer, L. (1994):** Oxidative damage to proteins: spectrophotometric method for carbonyl assay. *Methods Enzymol.* 233, 357-363.
- Rotruck J.T., et al. (1973).** Selenium: biochemical role as a component of glutathione peroxidase. *Science*, 179 (4073), 588-590.
- Ruiz-Meana M., Pina P., Garcia-Dorado D., et al. (2004):** Glycine protects cardiomyocytes against lethal re-oxygenation injury by inhibiting mitochondrial permeability transition. *J. Physiol.* 558, 873-882.
- Ruschitzka F., Borer J.S., Krum H., Flammer A.J., Yeomans N.D., Libby P., et al. (2017):** Differential blood pressure effects of ibuprofen, naproxen, and celecoxib in patients with arthritis: the PRECISION-ABPM (Prospective Randomized Evaluation of Celecoxib Integrated Safety Versus Ibuprofen or Naproxen Ambulatory Blood Pressure Measurement) Trial, *Eur. Heart J.* 38(44),3282-3292.
- Samuel S.A., Francis A.O., Anthony O.O. (2018):** Role of the Kidneys in the Regulation of Intra- and Extra-Renal Blood Pressure. *Ann. Clin. Hyperten.* 2, 048-058
- Senthilkumar R., Viswanathan P., Nalini N. (2004):** Effect of glycine on oxidative stress in rats with alcohol induced liver injury. *Pharmazie.* 59(1), 55-60.
- Shafiekhani M., Ommati M.M., Azarpira N., Heidari R., Salarian A.A. (2019):** Glycine supplementation mitigates lead-induced renal injury in mice. *J. Exp. Pharmacol.* 11, 15-22. <https://doi.org/10.2147/JEP.S190846>
- Sherve K., Gerard C.J., Neher J.O. (2014):** Cardiovascular effects of NSAIDs. *Am. Acad. Fam Physicians.* 90(4), 256A-256B
- Simon J.P., Evan Prince S. (2018):** Diclofenac-induced renal toxicity in female Wistar albino rats is protected by the pretreatment of aqueous leaves extract of *Madhuca longifolia* through suppression of inflammation, oxidative stress and cytokine formation. *Biomed. Pharmacother.* 98, 45-51.
- Singh D.P., Borse S.P., Nivsarkar M. (2017):** Overcoming the exacerbating of ranitidine on COXIBS-induced small intestinal toxicity with quercetin: providing a complete GI solution. *Chem Biol Interact.* 272, 53-64.

- Snowden S., Nelson R. (2011):** The effects of nonsteroidal anti-inflammatory drugs on blood pressure in hypertensive patients. *Cardiol. Rev.* 19(4), 184-91.
- Stempak D., Gammon J., Klein J., Koren G., Baruchel S. (2002):** Single-dose and steady-state pharmacokinetics of celecoxib in children. *Clin. Pharmacol. Therapeut.* 72, 490-497.
- Syed M., Skonberg C., Hansen S.H. (2016):** Mitochondrial toxicity of diclofenac and its metabolites via inhibition of oxidative phosphorylation (ATP synthesis) in rat liver mitochondria: possible role in drug induced liver injury (DILI). *Toxicol. in Vitro.* 31, 93-102.
- Todorich B., Olopade J.O., Surguladze N., et al. (2011):** The mechanism of vanadium-mediated developmental hypomyelination is related to destruction of oligodendrocyte progenitors through a relationship with ferritin and iron. *Neurotoxicol. Res.* 19, 361-373.
- Varshney R., Kale R.K. (1990):** Effect of calmodulin antagonists on radiation-induced lipid peroxidation in microsomes. *Int. J. Radiat Biol.* 58, 733-743.
- Wolff S.F. (1994):** Ferrous ion oxidation in the presence of ferric ion indicator xylenol orange for measurement of hydrogen peroxides. *Methods Enzymol.* 233, 182-189.
- Wadei H.M., Textor, S.C. (2012):** The role of the kidney in regulating arterial blood pressure. *Nat. Revs Nephrol.* 8(10), 602-609.
- Wang Z., Zhang J., Wang L., Li W., Chen L., Li J., Zhao D., Zhang H., Guo X. (2018):** Glycine mitigates renal oxidative stress by suppressing Nox4 expression in rats with streptozotocin-induced diabetes, *J. Pharmacol. Sci.* 137 (4), 387-394.
- Wu G., Fang Y.Z., Yang S, et al. (2002):** Glutathione metabolism and its implications for health. *J. Nutr.* 134, 489-492.
- Zerbini L. F., Tamura R. E., Correa R. G., Czibere A., Cordeiro J., Bhasin M., et al. (2011):** Combinatorial effect of Cyclooxygenase inhibitors and NF- κ B inhibitors in ovarian cancer therapy. *PLoS One.* 6(9), 24285.

UNIVERSITY OF IBADAN LIBRARY