

Assessment of *Thevetia neriifolia* Juss. Toxicity as a Rodenticide in Wistar Rats

Olajumoke O. Fayinminnu (Corresponding Author)

Department of Crop Protection and Environmental Biology, University of Ibadan, Ibadan,
Nigeria

Funmilayo G. Adebisi

Agricultural Biochemistry and Nutrition Unit, Department of Animal Science, University of
Ibadan, Ibadan, Nigeria

Ebunoluwa I. Fashola, Temitayo A. Gbemibade

Department of Crop Protection and Environmental Biology, University of Ibadan, Ibadan,
Nigeria

Olugbenga A. Ogunwole

Agricultural Biochemistry and Nutrition Unit, Department of Animal Science, University of
Ibadan, Ibadan, Nigeria

Received: February 17, 2022 Accepted: May 20, 2022 Published: May 26, 2022

doi:10.5296/jas.v10i3.19900

URL: <https://doi.org/10.5296/jas.v10i3.19900>

Abstract

Problems of rodents cannot be over underlined as a household and agricultural pest, damaging the crops on the field and stored produce thereby reducing qualities of produce. Controlling rodents using physical, biological and chemical methods have resulted in a slow rate success, several dangers on humans, animals and environment, hence they are discouraged. *Thevetia neriifolia* has been found to be a rich source of pesticide substance that could be used in crop protection; thus, its powdered form could be used as a baseline for potential natural rodenticide bait. The rodenticide capability of *Thevetia neriifolia* was evaluated using 50 female Wistar rats weighing 80 ± 10 g which were acclimatized for seven days. The rats were allotted to ten treatments, each replicated five times. There was a Standard Reference Feed (diet) (SRF). The test samples were milled (with 2 mm sieve) sun-dried seed (SS), sun-dried leaf (SL) and sun-dried stem bark (SB). Each sample was incorporated at 15%, 30% and 45% into the reference diets. The allotments were in a completely randomized design. Experimental rats were fed with separate diets and supplied water *ad-libitum* for seven days. Results showed

significant differences ($p < 0.05$) in all the parameters. Rats on SS and SB at 45% inclusion levels had the lowest body weight reduction. Also, the lowest feed intake was observed in rats fed 45% SS, while those on 15% SL and SRF had the highest feed intake. Packed cell volume and hemoglobin were the only hematological parameters that differed significantly ($p < 0.05$) at 15% and 45% SL inclusion levels. The serum biochemical parameters were not affected by the treatments ($p > 0.05$). Organ sections (livers, hearts and kidneys) showed moderate congestion of sinusoids, multiple foci of mononuclear cells and congestion of renal blood vessels of rats on 45% SS inclusion level. No mortality or abnormal behavioural changes were observed among animals on SRF. Varying dietary inclusion levels of test samples resulted in rat mortalities which was attributed to cardiac glycosides. Rats on 45% SS died faster within 96 hours than those on corresponding inclusion levels of SB and SL which died after 216 hours. Therefore, *Thevetia neriifolia* has rodenticide capability and could be used as baits for rats.

Keywords: *Thevetia neriifolia*, natural rodenticides, leaf, stem bark, seed, toxicity, rats

1. Introduction

Rats are known for the damage they cause by urinating on food, chewing on valuable materials and eating stored produces, they can also chew electric wires which can lead to fire incidents. They are most famous for spreading the highly infectious bubonic plague in the middle ages (Wilmshurst *et al.*, 2008). Rodenticides (rodent poisons) are categories of pest control chemicals intended to kill rodents attacking fields and stored products (Plunkett and Signe, 2001). Synthetic rodenticides are man-made organic chemicals that are synthesized. They are provocative due to secondary destruction and their risks to humans, pets, wildlife and the environment (Meerburg *et al.*, 2009). Examples of synthetic rodenticides are Warfarin, Anticoagulants and metal phosphides (zinc phosphide). Fayinminnu *et al.* (2013) posited that natural pesticides of plant origin are safe, cheap, readily available, biodegradable and are environmentally friendly. Other plants also contain secondary metabolites which could be used to control rodents, particularly, rats. Oji *et al.* (1994) reported how experimental rats that consumed baits containing lethal doses of *Thevetia neriifolia* displayed poisoning symptoms within 30 minutes and later died between 2 to 3 hours after treatment.

Thevetia neriifolia belongs to the family of Apocynaceae. The plant is a native of Central and South America, West Indies now frequently grown it throughout the tropical and sub-tropical regions. Seeds of *Thevetia neriifolia* contained about 35% protein which is comparable in quality to soyabean meal (Nair *et al.*, 1982). *Thevetia neriifolia* plant also contained cardiac glycosides, which include peruvoside and nerifolin, having a relatively high therapeutic index that could be compared with digoxin (Mantu and Sharma, 1980; Gata-Gonçalves *et al.*, 2003 and Omolara and Ibiyemi, 2007). Chemical and pharmacological studies demonstrated that the whole plant, especially the seeds, contained potentially toxic cardiac glycosides (thevetins A and B, thevetoxin, nerifolin, peruvoside and ruvoside) (Aguilar and Zolla, 1982; Fayinminnu *et al.*, 2017).

Thevetia neriifolia is hardly utilised either in human diets or livestock feed due to the presence of anti-nutritional toxic components such as phenols, terpenoids, oxalates, phytic

acid and saponins in the seeds (Daniel and Sabnis, 1978; Begum *et al.*, 1993; Abe *et al.*, 1995; Oji and Okafor, 2000). All parts of *Thevetia neriifolia* are very toxic, particularly the sap and the oily seeds (Langford and Boor, 1996). Human exposure to *Thevetia neriifolia* has occurred when tea brewed from plant parts is consumed or after consuming leaves, flowers or seeds from plants containing cardiac glycosides (Langford and Boor, 1996). A report from Australia had revealed 27% of plant poisonings which involved Oleander (Shawn and Pearn 1979). A small amount of the plant can have toxic effects. Preparation of the plant by boiling or drying does not deactivate the toxins (Roberts *et al.*, 2006). Deaths have been reported from drinking herbal tea containing Oleander (Haynes *et al.*, 1985). *Thevetia neriifolia* ingestion can irritate contacted membrane, nausea, vomiting, abdominal pain, increased salivation, diarrhoea, headache, altered mental status, mydriasis, peripheral neuritis, and cardiovascular complication (Langford and Boor, 1996).

All the parts (seeds, leaves, fruits and roots) of *Thevetia neriifolia* are essential sources of bioactive compounds with great potential (Oderinde and Oladimeji, 1990) in the manufacturing of insecticides (Reed *et al.*, 1982; Ambang *et al.*, 2007) potential rodenticides (Oji *et al.*, 1993; Oji *et al.*, 1994; Oji and Okafor, 2000; Fayinminnu *et al.*, 2017) fungicides (Kurucheve *et al.*, 1997; Gata-Gonçalves *et al.*, 2003) and bactericides (Saxena and Jain, 1990; Gata-Gonçalves *et al.*, 2003; Obasi and Igboechi, 1991). Gata-Gonçalves *et al.* (2003) also reported the antifungal effect of *Thevetia neriifolia* against *Cladosporium cucumerinum*. Crude extracts from *Thevetia neriifolia* seeds after maceration in different organic solvents were reported to inhibit the development of *Phytophthora megakarya*, a causal agent of black pod disease of *Theobroma cacao* (Ambang *et al.*, 2010). These toxic attributes of *Thevetia neriifolia* are yet to be adequately tested for rodents which have remained one of the most destructive pests of agriculture. This research was therefore aimed at evaluating the capability of *Thevetia neriifolia* parts (seed, leaf and stem bark) as a rodenticide using Wistar rats.

The destructive tendencies of rodents in the household, as well as agricultural pests, cannot be overemphasized. Several damages have been caused by rats on crops in the field and stored produce thereby rendering the produce useless (Meerburg *et al.*, 2009).

Earlier attempts to control rodents include mostly physical such as dogs, cats and traps (Meyer, 2003) and chemical methods which include rodenticides and poison-baiting. The use of traps as a physical means has been successful but at a slow rate, as the number of rats caught at a time was dependent on the number of set traps. Also, the use of cats or dogs in a predator/prey relationship represents a biological method that lasted for ages but not without its limitations. These include contamination of the dogs or cats' food and water by urine and droppings of the rats. Also, rats' bites on dogs or cats can occur leading to infections and diseases. Synthetic chemicals for killing rodents attacking fields and stored products have been reportedly effective (Plunkett and Signe, 2001). However, several hazards associated with this method of control had been traced to accidental ingestion by non-targeted animals and are thus discouraged (Meerburg *et al.*, 2009).

Most research on extracts of *Thevetia neriifolia*, were not only in human health but also in agriculture, as a potential pesticide (Aguilar and Zolla, 1982) suitable for crop protection

(Mollah, and Islam 2007). However, the present study using *Thevetia neriifolia* in powdered form could serve as a baseline study aimed at determining the plant as a natural condiment for baiting rats. This study was therefore intended as a panacea for pests' rapid build-up on the field as well as in the mitigation of associated difficulty of produce storage devoid of hazardous residual effect on food and environment.

2. Method

2.1 Study Area

The study area University of Ibadan lies between longitude 7°27.05 north and 3°53.74 of the Greenwich Meridian east at an altitude of 200 m above sea level. The average temperature and relative humidity of the location are between 23-42 °C and 60-80%, respectively (SMUI 2018). The site has a mean annual rainfall of 1110.1mm. The rainfall has bimodal distribution characteristics with the peak in July and September. The experiment was undertaken at the Central Animal House, Department of Physiology, College of Medicine and the Clinical Pathology and Histopathology Laboratories of the Department of Veterinary Pathology, Faculty of Veterinary Medicine, all in the University of Ibadan, Ibadan, Nigeria.

2.2 Sourcing of *Thevetia Neriifolia* Leaves, Seeds and Stem Bark

The plant material used for this experiment was *Thevetia neriifolia*. The plant parts of interest were the leaves, seeds and stem bark, which were collected early in the morning (6.00 am) from the Faculty of Education, University of Ibadan. *Thevetia neriifolia* plant parts collected were sun-dried at an ambient temperature of 26±4°C and relative humidity of 84.5% for a period of 10 days. Different dried plant parts were separately milled with a hammer mill and were made to pass through a 2.0 mm wire mesh sieve diameter. The powdered *Thevetia neriifolia* parts were mixed with granulated animal feed at 15, 30 and 45% weight/weight inclusion levels of 100g of Standard Reference Feed (SRF).

2.3 Experimental Set-up

Beforehand the arrival of the rats, the rat house and cages were properly prepared and sanitized. Cages were appropriately organized and fitted with drinkers which could easily drip water once imbibed by rats. Feeders were properly fixed to eliminate feed spillage. Female weanling Wistar rats (n=50) weighing 80±10g used for this study were obtained from the Central Animal House, Department of Physiology, College of Medicine, University of Ibadan. Acclimatisation of the experimental rats was for a period of seven days (before experimentation) at 27±2°C, with 12-hour light, 12-hour dark cycles and relative humidity of 75-80%. Individual animals were kept in cleaned wooden cages for three weeks (21days). The rats were fed on locally sourced SRF growers mash feed during acclimatisation for seven days. Feed and water were given to rats *ad libitum*. All rats were handled in accordance with the guidelines for care and use of laboratory animals as stated by the Animal Care and Use Research Ethics Committee (Clark *et al.*, 1997) as well as the Guidelines for the Handling of Laboratory Animals at the College of Medicine, University of Ibadan, Ibadan, Nigeria.

The rats were randomly allocated to ten treatments; individually treatment was replicated five

times in a completely randomized design. The treatments were: Control (SRF-100g); 15% *Thevetia neriifolia* leaves powder-LP (15g to 85g of SRF); 30% *Thevetia neriifolia* LP (30g to 70g of SRF); 45% *Thevetia neriifolia* LP (45g to 55g of SRF); 15% *Thevetia neriifolia* stem bark powder- SBP (15g to 85g of SRF); 30% *Thevetia neriifolia* SBP (30g to 70g of SRF); 45% *Thevetia neriifolia* SBP (45g to 55g of SRF); 15% *Thevetia neriifolia* seed powder-SP (15g to 85g of SRF); 30% *Thevetia neriifolia* SP (30g to 70g of SRF); 45% *Thevetia neriifolia* SP (45g to 55g of SRF).

The body weights of the rats were taken with a weighing scale on day 1 of the experiment and were repeated weekly for two weeks to assess the weight gain/loss. The percentage daily feed intake of rats was also determined during the experimental period using the formula:

$$\frac{\text{Weight of feed offered (g)} - \text{the weight of the leftover feed (g)}}{\text{Weight of feed offered (g)}} \times 100\%$$

Observations on treatments toxicity were made on behavioural patterns of the rats during feeding. These include loss of appetite, tremor, convulsion, vomiting, weight loss/ gain, paralysis (Fayinminnu *et al.*, 2017). On day 21 of feeding the experimental diets, all surviving rats were sacrificed by cervical dislocation. The rats were dissected immediately to remove internal organs: liver, kidney and heart for histopathological examinations. Blood (2 mL) was sampled with capillary tubes into vacutainer EDTAK3 for hematological analysis. Another blood (3 mL) was sampled into a vacutainer bottle without anticoagulant and the serum was harvested for serum biochemical indices determination. Histopathological examinations were carried out on the harvested organs.

2.4 Hematological and Serum Biochemistry Analyses

Packed cell volume (PCV) was determined with microhaematocrit method as described by (Mitruka and Rawnsley, 1997). Hemoglobin was determined using cyano methemoglobin method (Gibson and Harrison, 1945). Red blood cell count (RBC) was by improved Neubauer hemocytometer (Schalm *et al.*, 1975). White blood cell count (WBC) and platelets were determined by the improved Neubauer (Schalm *et al.*, 1975). The leucocyte differentials (monocytes, lymphocytes and neutrophils) were determined by scanning Giemsa's-stained slides in the classic manner (Schalm *et al.*, 1975). A drop of blood was placed at the end of a grease-free slide.

Alkaline phosphatase (ALP), alanine aminotransferase (ALT) and aspartate aminotransferase (AST) in the serum were obtained with the procedure of Reitman and Frankel (1957).

2.5 Histopathological Analysis

All tissues from harvested organs (liver, kidney and heart) of each experimental animal were fixed in Bouin's fluid for 24 hours. The tissues were dehydrated at different stages of ethanol concentrations; 70, 95 and 100% ethanol, each for 2 hours. The tissues were moved to 100% xylene to clear the ethanol from the tissues for one hour. The tissues were thereafter placed in molten paraffin wax. Molten wax was applied 3 times for 2 hours each time in a wax oven of fairly high temperature before embedding. The tissues were positioned in molten paraffin

wax within cassette- mould from wax dispenser and left to solidify.

The tissues were trimmed with a micro-tome and micro-tome blade and exposed for sectioning microscopic examination; the histopathological procedures were carried out in a stepwise protocol as follows: fixation, dehydration, clearing, infiltration, embedding, blocking, sectioning and staining. Tissue specimens were collected from rats` livers and kidneys and rapidly fixed in 10% neutral buffered formalin. After proper fixation, thin paraffin sections were routinely prepared and stained with hematoxylin and eosin (H & E) stain for microscopical examination according to Drury and Wallington (1980) through the light microscope (x400) and the readings recorded.

2.6 Statistical Analysis

Data were analysed using Analysis of Variance (ANOVA), while means were separated using Least Significant Difference (LSD) at $p < 0.05$ probability level.

3. Results

3.1 Behavioural/Morphological Observations on Female Wistar Rats

Observations on experimental rats treated with leaf, stem bark and seed powders at different inclusion levels (15, 30 and 45%) revealed loss of appetite, weight loss, convulsion, vomiting, ataxia and paralysis of hind limbs.

3.2 Toxic Effects of Varying Inclusions of *Thevetia neriiifolia* treatments on the Feed Intake of Female Wistar Rats

The results in Fig.1 revealed significant differences ($p < 0.05$) in feed intake (g) of rats on LP, SBP and SP treatments at the different inclusion levels (15%, 30% and 45%) in this study. Higher feed intake of 68.33, 54.40 and 52.47% were obtained, respectively from rats on LP, SBP and SP treatments at 15% inclusion levels which differed significantly ($p < 0.05$) from other inclusion levels. The lowest feed intake of 64.67, 49.80 and 44.13% were, respectively obtained from rats on the LP, SBP and SP treatments at 45% inclusion levels. Rats on SRF however, had the highest feed intake of 90.06, 93.33 and 93.13g for leaf, stem bark and seed powder treatments, respectively which were highly significant from the treated animals.

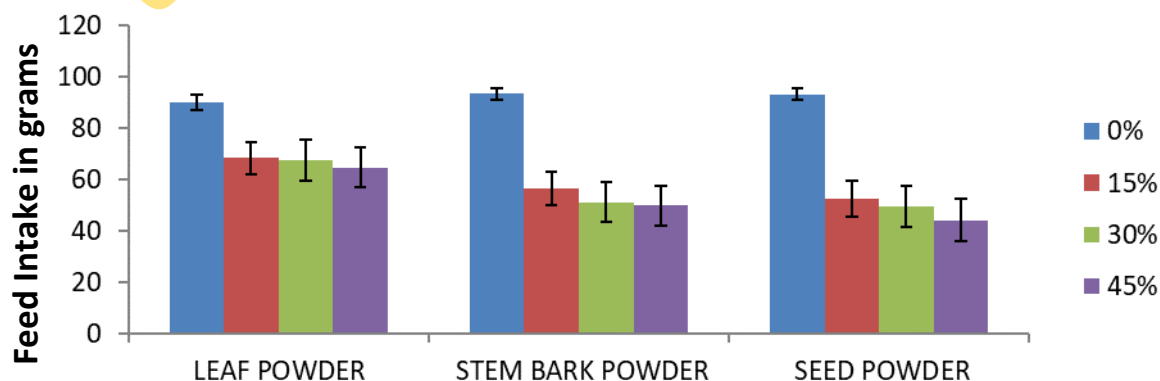


Fig. 1. Toxic Effects of various *Thevetia neriiifolia* treatments on the Feed Intake powder (g)

of female Wistar rats

3.3 Effects of *Thevetia neriifolia* Treatments on Body Weight of Female Wistar Rats

The toxic effects of varying dietary inclusions of *Thevetia neriifolia* powder on the body weight of Wistar rats are shown in Figure 2. At week 1, rats on SRF diets had BW of 86.0g which was significantly higher ($p < 0.05$) than those on other experimental diets. Rats on other diets had similar ($p > 0.05$) body weights. At week 2, rats on SRF had BWG of 97.0g which was significantly higher ($p < 0.05$) than those on other treatments. Rats on fed diets with varying *Thevetia* inclusions had similar ($p < 0.05$) progressive weight losses. However, rats on SP at 45% inclusion had the least body weight of 33.25g similar ($p > 0.05$) to those on 45% SB (41.25 g), while rats on 15% LP had significantly higher ($p < 0.05$) body weight of 51.25g.

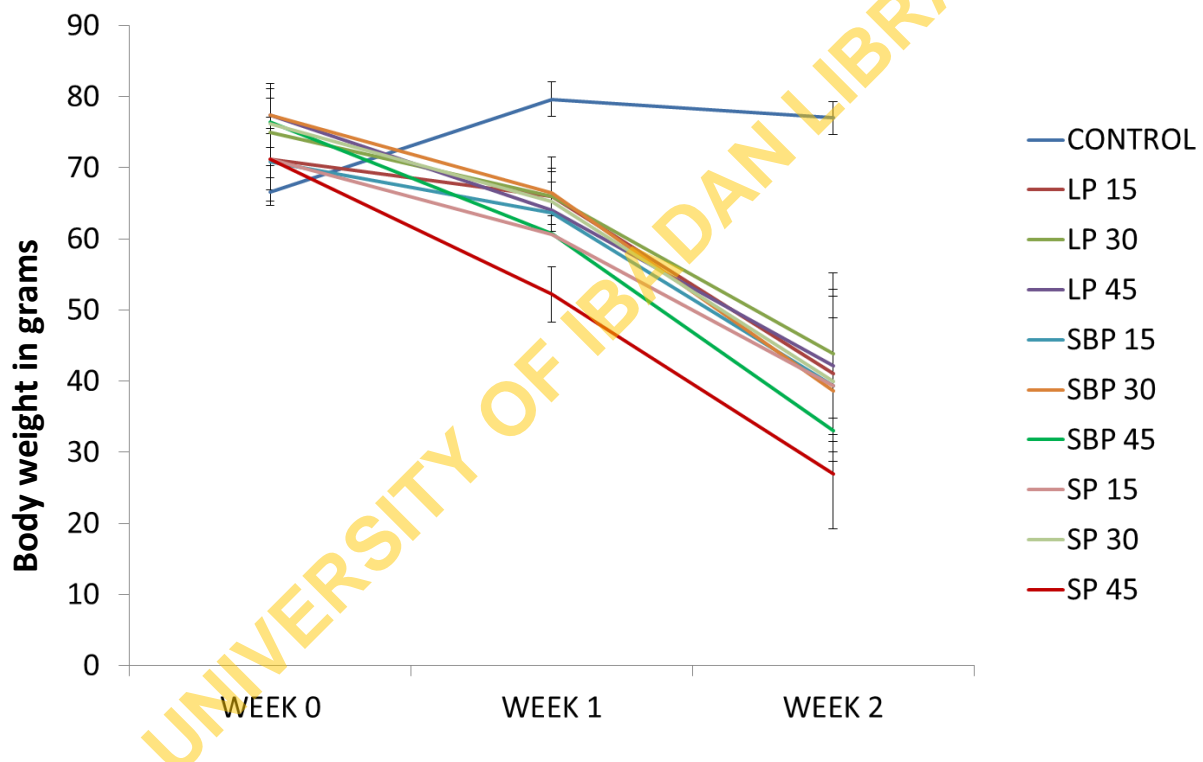


Fig. 2. Toxic Effects of varying concentrations (in %) of *Thevetia neriifolia* powder on the body weight (g) of female Wistar rats

LP = Leaf Powder, SBP = Stem Bark Powder, SP = Seed Powder

3.4 Effects of dietary *Thevetia neriifolia* on Hematology of Female Wistar Rats

Tables 1.1a and 1.1b revealed no significant differences ($p > 0.05$) in the hematological parameters: RBC, WBC, NEUT, LYMP, MONO, EOSI and Platelet. Significant differences ($p < 0.05$) were observed for PCV and Hb. The control of both PCV and Hb were not significantly different ($p > 0.05$) from leaf powder at 15% inclusion level but were significantly different ($p < 0.05$) from the leaf at 30% inclusion level. However, other treatments; leaf at 45%, stem bark and seed at 15, 30 and 45% inclusion levels, respectively

were lethal doses causing mortality as denoted with death.

Table 1.1a. Toxic Effects of varying levels of *Thevetia nerifolia* on the hematological parameters of female Wistar rats

Treatment	PVC%	HB	RBC ($\times 10^3/\mu\text{L}$)	WBC ($\times 10^3/\mu\text{L}$)	NEUT ($\times 10^3$)
Control	39.33 ^a \pm 0.6 7	13.33 ^a \pm 0.64	6.73 ^a \pm 0.25	6.78 ^a \pm 0.76	30.66 ^a \pm 4.06
Leaf 15%	40.00 ^a \pm 1.1 5	13.63 ^a \pm 0.67	6.78 ^a \pm 0.40	5.92 ^a \pm 1.84	26.00 ^a \pm 2.31
Leaf 30%	34.33 ^b \pm 1.3 3	11.60 ^b \pm 0.87	5.79 ^a \pm 0.74	9.18 ^a \pm 1.75	31.33 ^a \pm 4.06
Leaf 45%	Died	Died	Died	Died	Died
Stem 15%	Bark Died	Died	Died	Died	Died
Stem 30%	Bark Died	Died	Died	Died	Died
Stem 45%	Bark Died	Died	Died	Died	Died
Seed 15%	Died	Died	Died	Died	Died
Seed 30%	Died	Died	Died	Died	Died
Seed 45%	Died	Died	Died	Died	Died
LSD \leq 0.05	3.77	1.82	1.01	5.29	12.35
			NS	NS	NS

Means within the same column followed by the same letter(s) are not significantly different at $p < 0.05$ using LSD: Least Significant Difference

NS= Not significant, PCV = Packed cell volume, Hb = Hemoglobin count, RBC = Red blood cell count, WBC = White blood cell count, Neut = Neutrophil

Table 1.1b. Toxic Effects of varying levels of *Thevetia neriifolia* on the hematological parameters of female Wistar rats

Treatment	LYMP(x10 ³)	MONO(x10 ³)	EOSI(x10 ³)	PLATELET(x10 ³ /μL)
Control	66.33 ^a ±3.48	1.66 ^a ±0.33	1.66 ^a ±0.33	1037.66 ^a ±524.75
Leaf 15%	66.00 ^a ±2.08	1.66 ^a ±0.33	3.00 ^a ±0.58	953.33 ^a ±374.19
Leaf 30%	66.33 ^a ±4.91	1.00 ^a ±0.00	1.33 ^a ±0.88	1703.33 ^a ±347.51
Leaf 45%	Died	Died	Died	Died
Stem Bark 15%	Died	Died	Died	Died
Stem Bark 30%	Died	Died	Died	Died
Stem Bark 45%	Died	Died	Died	Died
Seed 15%	Died	Died	Died	Died
Seed 30%	Died	Died	Died	Died
Seed 45%	Died	Died	Died	Died
LSD≤0.05	12.73	0.94	2.21	1024.14
	NS	NS	NS	NS

Means within the same column followed by the same letter(s) are not significantly different at $p < 0.05$ using LSD: Least Significant Difference

NS= Not significant, LYMP = Lymphocytes, MONO = Monocytes, EOSI = Eosinophiles

3.5 Toxic Effects of Varying Levels of *Thevetia Neriifolia* Plant Parts on the Serum Biochemical Parameters of female Wistar Rats

Table 2 showed no significant differences ($p > 0.05$) in the biochemical parameters (AST and ALT) of experimental rats. The LP at 15% and 30% dietary inclusion level treatments of leaf dietary inclusion levels showed no significant differences ($p > 0.05$) when compared with the control. However, other treatments; LP at 45%, SB and SP at 15, 30 and 45% *Thevetia* inclusion levels, respectively were lethal doses that caused mortality as denoted with died.

Table 2. Toxic Effects of varying levels of *Thevetia neriifolia* plant parts on the Serum biochemical parameters of female Wistar rats

Treatment	AST (U/I)	ALT (U/I)
Control	120.93 ^a ±4.71	35.40 ^a ±2.77
Leaf 15%	130.01 ^a ±4.82	40.66 ^a ±7.95
Leaf 30%	114.83 ^a ±7.21	35.19 ^a ±4.31
Leaf 45%	Died	Died
Stem Bark 15%	Died	Died
Stem Bark 30%	Died	Died
Stem Bark 45%	Died	Died
Seed 15%	Died	Died
Seed 30%	Died	Died
Seed 45%	Died	Died
LSD≤0.05	19.72	18.89
	NS	NS

Means within the same column followed by the same letter(s) are not significantly different at $p < 0.05$ using LSD: Least Significant Difference

NS= Not significant, AST = Aspartate amino transferase, ALT = Alanine amino transferase

3.6 Toxicity of *Thevetia Neriifolia* Leaf, Stem Bark and Seed at Various Inclusion Levels on the Histology of Heart, Kidney and Liver in Female Wistar Rats

Plate 1: Histological examination results of the heart, kidney and liver of the experimental female Wistar rats revealed the control showing no visible lesion or any abnormal clinical signs for all the vital organs that were examined. The treatment of leaf powder at 15% inclusion level showed no visible lesion in the heart examination but mild proteinaceous filtrates in the kidney and marked vacuolar changes of hepatocytes in the liver. Leaf powder at 45% inclusion level recorded multiple aggregates of mononuclear cells in the heart, mild congestion of renal blood vessels in the kidney and vacuolar change and also thinning of

hepatic cords were observed for liver organ.

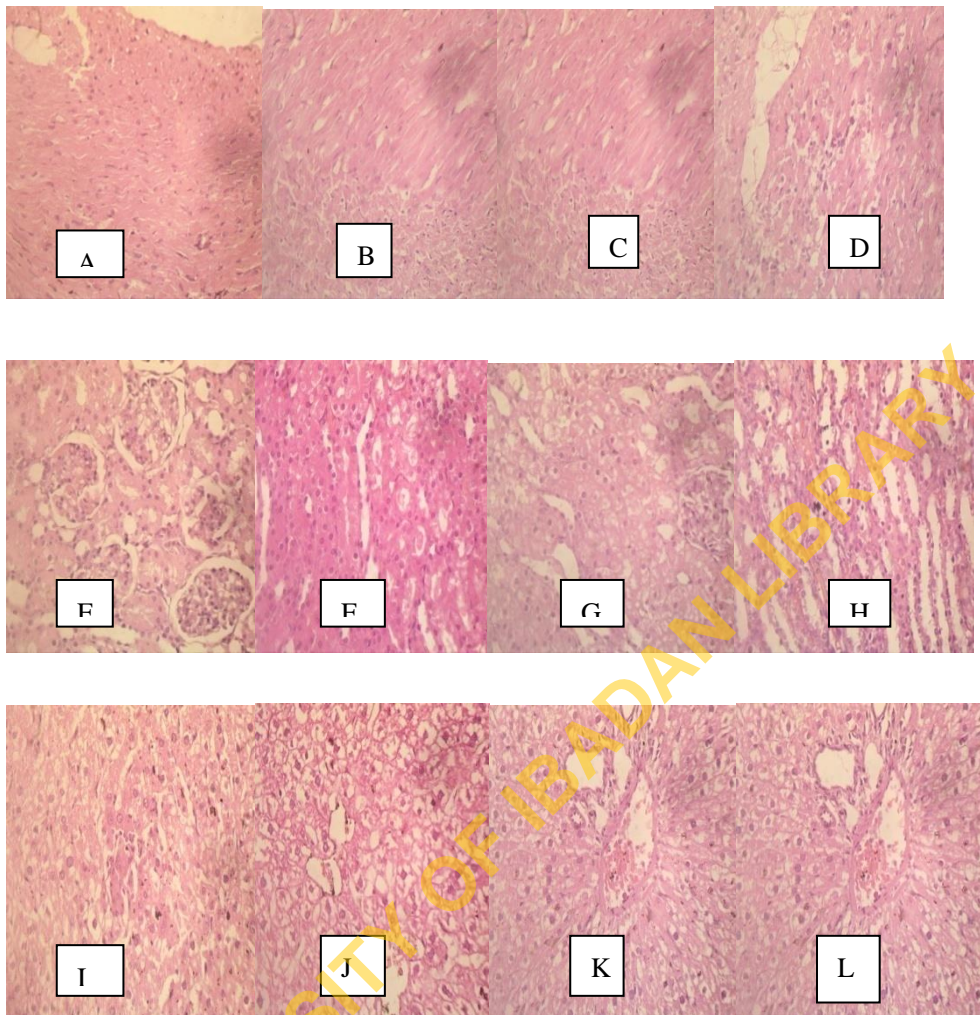


Plate 1. Photomicrographs of Histological section of heart, kidney and liver of *Rattus norvegicus* fed with *Thevetia nerifolia* leaf at various inclusion levels

Heart (A-D): A-Control: No visible lesion, B-15%: No visible lesion, C-30%: No visible lesion, D-45%: Aggregates of monocellular cells

Kidney (E-H): E-Control: No visible lesion, F-15%: Presence of mild proteinaceous filtrates, G -30%: Presence of vacuolar of the epithelial cells, H-45%: Congestion of blood vessel

Liver (I-L): I-Control: No visible lesion, J- 15%: Marked vacuolar hepatocytes, K-30%: Cellular necrosis, L-45%: Vacuolar change and mild hepatic cords

H& E Magnification x400

The postmortem for the *Thevetia nerifolia* stem bark powder inclusion levels on heart, liver and kidney organs were examined. The inclusion level at 15% showed thinning and detachment of myocardial fibres in the heart, marked sloughing off of tubular epithelium in the renal medulla in the kidney and cellular necrosis and associated thinning of hepatic cords in the liver examined. Thinning and detachment of myocardial fibres were also recorded in

the heart of stem bark at 30%, mild congestion of interstitial renal blood vessel was recorded in kidney and Kupffer cell hyperplasia and congestion of hepatic sinusoids were recorded in the liver, respectively. Extensive foci of myocardial hemorrhages were observed in the heart of stem bark at 45%, multi-focal coagulation of tubules in the kidney and reticulated cytoplasmic appearance of hepatocytes in the liver (Plate 2).

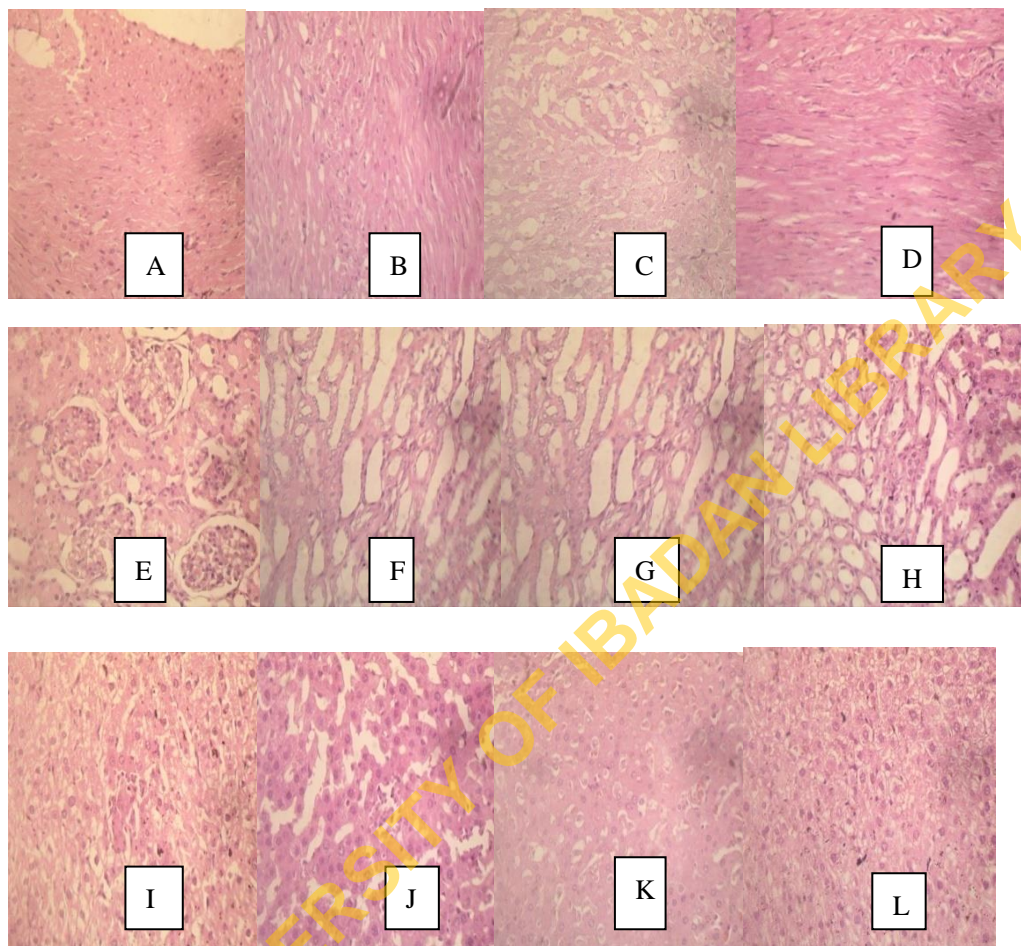


Plate 2. Photomicrograph Histological section of heart, kidney and liver of *Rattus norvegicus* fed with *Thevetia nerifolia* stem bark at various inclusion levels

Heart (A-D): A- Control: No visible lesion, B- 15%: Thinning and detachment of myocardial fibres, C-30%: Thinning and detachment of myocardial fibres, D-45%: Extensive foci of myocardial haemorrhages.

Kidney (E-H): E-Control: No visible lesion, F- 15%: Marked sloughing from tubular epithelial in the renal medulla,

G-30%: Mild congestion of interstitial renal blood vessel, H-45%: Multi-focal coagulation of tubules

Liver (I-L): I- Control: No visible lesion, J-15%: Cellular necrosis and associated thinning of hepatic cords, K-30%: Kupffer cell hyperplasia and congestion of hepatic sinusoids, L-45%: Reticulated cytoplasmic appearance of hepatocytes

H& E Magnification x400

Clinical examination at postmortem of the heart of female Wistar rats fed with seed showed extensive foci of myocardial hemorrhages, kidney showed multi-focal of coagulation of tubules, while liver showed mild multi-focal of aggregates of mononuclear cells. The treatment of seed at 30% revealed extensive foci of myocardial hemorrhages in the heart, multi-focal coagulation of tubules in the kidney and mild multi-focal aggregates of mononuclear cells in the liver.

Severe multiple foci of mild mononuclear cells were observed in heart of the seed at 45%, congestion of renal blood vessels and glomerular tufts in the kidney, while moderately congestion of sinusoids was recorded in the liver (Plate 3).

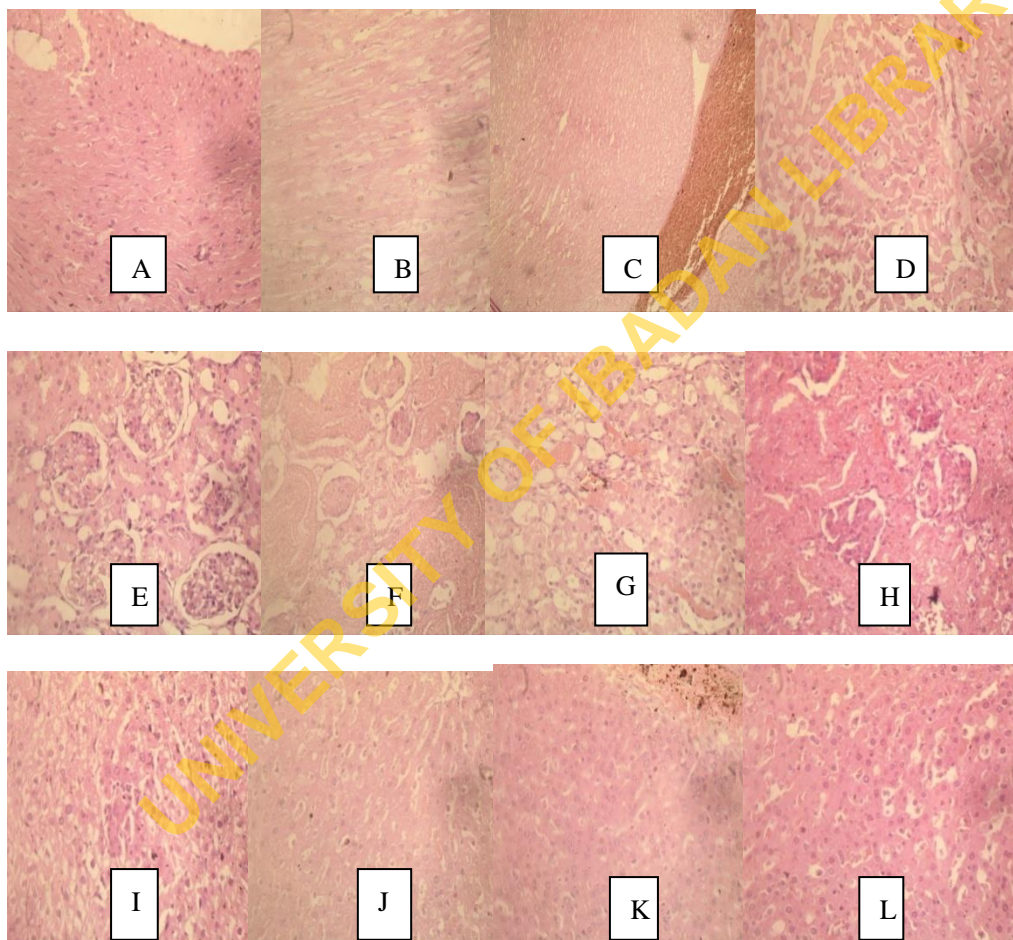


Plate 3. Photomicrograph Histological sections of heart, kidney and liver of *Rattus norvegicus* fed with *Thevetia neriifolia* seed at various inclusion levels

Heart (A-D): A-Control: No visible lesion, B-15%: Extensive foci of myocardial hemorrhages, C-30%: Congestion of coronary blood vessels, D-45%: Multiple foci of mild mononuclear cells

Kidney (E-H): A-Control: No visible lesion, B-15%: Multi-focal coagulation of tubules, C-30%: Marked congestion of renal blood vessels, D-45%: Congestion of renal blood vessels

and glomerular tufts

Liver (I-L): A-Control: No visible lesion, B-15%: Mild multi-focal aggregates of mononuclear cells, C-30%: Congestion of portal vessels, D-45%: Moderately congestion of sinusoids

H& E Magnification x400

4. Discussion

4.1. Behavioural/Morphological Observations

Abnormal signs observed in the experimental animals during this study when fed different inclusion levels of *Thevetia nerifolia* plant parts increased with time. The animals went into a coma until death within two weeks of the experiment which agreed with reports from the early studies (Pahwa and Chatterjee, 1990; Oji *et al.*, 1994; Taiwo *et al.*, 2004). The control animals and those treated with 15 and 30% leaf powder inclusion levels did not show any abnormal behavioural signs and death in the study. The physiological/ abnormal signs and death shown by the experimental animals may be due to the presence of toxic and natural poison glycosides in all parts of *Thevetia nerifolia* (Weinhouse *et al.*, 1989 and Fayinminnu *et al.*, 2017).

4.2 Feed Intake and Body Weight

It was evident that *Thevetia nerifolia* leaf, stem bark and seed inclusion levels adversely affected the feed intake as well as the body weight of the female Wistar rats. The rats that were fed with control diets had a higher percentage feed intake which resulted in a progressive increase in body weights, also mortality rate recorded in this group was zero. However, other rats fed *Thevetia nerifolia* based diets had progressive weight losses and mortality at the second week period of the experiment. This could be that the feed was not palatable thereby making the animals to move away from eating therefore lower feed intake. This also conformed with previous studies of (Daniel and Sabnis, 1978; Oji *et al.*, 1993; Space *et al.*, 2003; Taiwo and Igbeneghu, 2014) reported that the unpalatable *Thevetia nerifolia* inclusions could cause a slight numbing sensation in rats with a feeling of heat in the mouth, thus resulting in low feed consumption and corresponding weight losses. The presence of cardiac glycosides in *Thevetia nerifolia* made it non-edible and due to their powerful cardiac action could result in the death of the treated animals.

4.3 Hematological Parameters

Among the hematological parameters considered in this study, only Packed cell volume (PCV) and Hemoglobin (Hb) revealed a marked difference in comparison with control. The treated experimental animals had reduced PVC and Hb. This could be because of the toxicity of cardiac glycerides such as glycosides (thetivins A and B) which had been reported as toxic agents. They are known to have direct stimulant actions on the smooth muscles of the intestine and blood vessels walls (Watt and Breyer-Brandwijk, 1962; Taiwo and Igbeneghu, 2014). Reduction in PVC and Hb in the experimental animals could also lead to leucopenia due to hemoglobin counts. However, Carpenter (1975), noted that fluctuations of PCV and Hb

may be associated with microcytic anemia in a prolonged manner of feeding. This is indicated as a sub-chronic effect of *Thevetia neriifolia* ingestion at 15% and 30% leaf inclusion levels, and death of the test rats fed other inclusion levels of the plant parts.

4.4 Serum Biochemical Parameters

The ALT and AST revealed no deviation against leaf powder inclusion levels when compared with the control. The ALT and AST enzymes that are produced in the liver are good indicators of liver cells damage (Gressner *et al.*, 2007). These enzymes are always present at low levels in the blood and may leak or escape from the liver cells, into the bloodstream thereby increasing the blood level (Sharma *et al.*, 2013). The increase and decrease of ALT and AST of rats on leaf powder-based diets compared to the control may be related to the findings of Arundel and Lewis (2007) that in the diagnosis of hepatotoxicity, a relationship between the toxin and subsequent liver damage has to be established which might be difficult. This could happen especially when an unusual drug is ingested (idiosyncratic reaction). This reaction may occur as dose/duration-dependent which usually happens as acute or sub chronic toxicity as revealed in this study (Trapenier, 2013).

4.5 Histology of Heart, Kidney and Liver Organs

Rats fed *Thevetia neriifolia* leaf, stem bark and seed at varying inclusion levels displayed nervous symptoms such as convulsion, paralysis of hind limbs, ataxia and coma before death. This may be due to aggregates of mononuclear cells, congestion of coronary blood vessels in the heart, marked vacuolar changes of the epithelial cells in the kidney and cellular necrosis, congestion of portal vessel which were also evident in the liver under histological examination which conformed to report of Taiwo *et al.* (2004). The liver of the experimental animals lost its architecture with increased degeneration of hepatic cells. Degeneration of hepatocytes denoted those hepatic cells were necrotic in which the cytoplasm was vacuolar (Kosanam and Boyina, 2015; El-Deeb *et al.*, 2007). Treated animals with the inclusion levels of *Thevetia neriifolia* leaf, stem bark and seed showed an increased degree of degeneration of livers, this could be linked to dose/duration dependent on the liver function enzymes. Death of the experimental animals as observed in this study might have occurred due to the core actions of the toxic cardiac glycoside agents namely thevetins A and B and other toxins. These poisons could have worked upon the heart, blood vessels and liver, thereby resulting in heart failure and general tissue anoxia, hepatic damage and renal failure (Taiwo *et al.*, 2004) and other ill health.

5. Conclusion

(1) *Thevetia neriifolia* seed inclusion levels (15, 30 and 45%) were more toxic due to higher concentrations of cardiac glycosides (Thevetins A and B) toxins over other parts of the plant. These toxins had higher toxic effects on the body weight, feed intake and organ histology (heart, kidney and liver) of female Wistar rats.

(2) Rats exposed to all seed inclusion levels died faster within 96 hours, than those exposed to stem bark and leaf which died within 216 hours. However, no mortality or abnormal behavioural changes were observed among animals in the control groups.

(3) *Thevetia neriifolia* various parts; leaf at 45%, stem bark and seed at 15, 30 and 45% inclusion levels could be used as a natural bait rodenticide

References

Abe, F., Iwase, Y., Yamauchi, T., & Nohara, T. (1995). Flavonol sinapol glycosides from leaves of *Thevetia peruviana*. *Phytochemistry*, 40, 577-581. [https://doi.org/10.1016/0031-9422\(95\)00316-Y](https://doi.org/10.1016/0031-9422(95)00316-Y)

Aguilar, A., & Zolla, C. (1982). Editada por la subdirección General Medica 196.

Ambang, Z., Ndongo, B. Petga, E. Ngoh Dooh, J. P., & Asanga, A. (2007). Effect of crude extracts of *Thevetia peruviana* seeds on development of leaf spot disease of groundnut (*Arachis hypogaea* L.) caused by *Cercospora* sp. *African Crop Science*. In: Kasem, Z.A., Mahmoud, M.A. and Shalabi, S.I. (eds) African Crop Science Conference Proceedings, ACSS, October, 27-31 2007 El-Minia, Egypt. 8., 797-800.

Ambang, Z., Ngoh, J. D., Essono, G., Bekolo, N., & Chewachongl, G. (2010). Effect of *Thevetia peruviana* seeds extract on in-vitro growth of four strains of *Phytophthora megakarya* CC. *POJ.*, 3(3), 70-76.

Arundel, C., & Lewis, J. H. (2007). Drug-induced liver diseases in 2006. *Curr. Opin. Gastroenterol*, 23(3), 244-254. <https://doi.org/10.1097/MOG.0b013e3280b17dfb>

Begum, S., Abii, O., Siddiqui, B. S., & Siddiqui, S. (1993). Constituents of the leaves of *Thevetia neriifolia*. *Journal of Natural Products*, 56, 613-617. <https://doi.org/10.1021/np50094a024>

Capenter, F. L. (1975). Bird hematocrits; effects of high altitude and strength of flight. *Comparative Biochem Physiol.*, 50A, 415-417. [https://doi.org/10.1016/0300-9629\(75\)90035-3](https://doi.org/10.1016/0300-9629(75)90035-3)

Clark, J. D., Gebhart, G. F., Gonder, J. C., Keeling, M. E., & Kohn, D. F. (1997). The 1996 Guide for the Care and Use of Laboratory Animals, *ILAR Journal*, 38(1), 41-48. <https://doi.org/10.1093/ilar.38.1.41>

Daniel, M., & Sabnis, S. D. (1978). Chemo taxonomical studies on Apocynaceae. *Indian Journal of Experimental Biology*, 16, 512-513.

Drury, R. A., & Wallington, E. A. (1980) Carleton's Histological Techniques. 5th Edition, Oxford University Press, New York, 195.

El-Deeb, A. E. A., Abd El-Aleem, I. M., & Sherin, S. G. (2007). Harmful effect of some insecticides on vital parameters of albino rats. *J. Egypt. Soc. Toxicol.*, 36, 53-60.

Fayinminnu, O. O., Fadina, O. O., & Adedapo, A. A. (2013). Efficacy study of bulk source of crude cassava water extract as post-emergence herbicide in cowpea (*Vigna unguiculata* (L.) Walp) production. *The Lesotho Journal of Agricultural Sciences*, 3(1), 61-75.

Fayinminnu, O. O., Tijani, S. O., & Fadina, O. O. (2017). Toxicity Assessment of Sub Lethal

Doses of Chlorpyrifos on the Kidney and Liver Organs of Male Wistar Rats. *International Journal of Biochemistry Research and Review*, 17(3), 1-15.

<https://doi.org/10.9734/IJBCRR/2017/31349>

Fayinminnu, O. O., Ogunwole, O. A., & Gbemilade, T. A. (2017). Evaluation of the Effects of Drying Methods on Phytochemicals in *Thevetia neriifolia* Parts as a Potential Rodenticide.

Biotechnology Journal International, 17(2), 1-11. <https://doi.org/10.9734/BJI/2017/29739>

Gata-Gonçalves, L., Nogueira, J. M. F., Matos, O., & Bruno, De Sousa, R. (2003). Photoactive extract from *Thevetia peruviana* with antifungal properties against *Cladosporium cucumerinum*. *J.Photochem. Photobiol.*, 70, 51-54.

[https://doi.org/10.1016/S1011-1344\(03\)00024-1](https://doi.org/10.1016/S1011-1344(03)00024-1)

Gibson, Q. H., & Harrison, D. C. (1945). An artificial standard for use in the estimation of haemoglobin. *Biochem. J.*, 39, 490-497. <https://doi.org/10.1042/bj0390490>

Gressner, O. A., Weiskirchen, R., & Gressner, A. M. (2007). Biomarkers of liver fibrosis: Clinical translation of molecular pathogenesis or based on liver-dependent malfunction tests. *Clin. Chim. Acta*, 381, 107-113. <https://doi.org/10.1016/j.cca.2007.02.038>

Haynes, B. E., Bessen, H. A., & Wightman, W. D. (1985). *Ann. Emerg. Med.*, 14, 350. [https://doi.org/10.1016/S0196-0644\(85\)80103-7](https://doi.org/10.1016/S0196-0644(85)80103-7)

Kosanam, S., & Boyina, R. (2015). drug-induced liver injury: a review. *Int. J. Pharmacol. Res.*, 5. <https://doi.org/10.7439/ijpr.v5i2.1507>

Kurucheve, V., Echilan, J. G., & Jayaraj, J. (1997). Screening of higher plants for fungi toxicity against *Rsolani in vitro*. *Indian Phytopathol*, 50, 235-241

Langford, S. D., & Boor, P. J. (1996). Oleander toxicity: an examination of human and animal toxic exposures. *Toxicology*, 109, 1-13. [https://doi.org/10.1016/0300-483X\(95\)03296-R](https://doi.org/10.1016/0300-483X(95)03296-R)

Mantu, D. E., & Sharma, A. K. (1980). Cardenolide contents in different genotypes of *Thevetia nerifolia* and *Nerum odorum*. *Nucleus*, 23, 218-225.

Meerburg, B. G., Singleton, G. R., & Kijlstra, A. (2009). Rodent-borne diseases and their risks for Public Health *Critical Reviews in Microbiology*, 35(3), 221-270. <https://doi.org/10.1080/10408410902989837>

Meyer, J. R. (2003). `Pest Control Tactics` Chapter 19, NC State University 4 November, 2003 Web. 20 January, 2010

Mitruka, B. M., & Rawnsley, H. M. (1977). Clinical Biochemical and Haematological Reference Value in Normal Experimental Animals. Masson Publication, New York, USA., ISBN-13: 9780893520069, pp: 21-64.

Mollah, J. U., & Islam, W. (2007). Toxicity of *Thevetia peruviana* (Pers) Schum extract to adults of *Callosobruchus maculatus* F. (Coleoptera: Bruchidae). *J. Agric Rural Dev.*, 5, 105-109. <https://doi.org/10.3329/jard.v5i1.1466>

- Nair, A. G. R., Gunasegaran, R., & Joshi, B. S. (1982). Chemical investigation of certain South Indian plants. *Indian Journal of Chemistry*, 21b, 979-980.
- Obasi, N. B., & Igboechi, A. C. (1991). Seed-oil distillates of *Thevetia peruviana* (SYN. *T. neriifolia*): analysis and antibacterial activity. *Fitoterapia*, 62, 159-162.
- Oderinde, R. A., & Oladimeji, G. R. (1990). Oil characteristics of *Thevetia peruviana* (Yellow Oleander) and *Pulmeria alba* (White frangipani), Riv. Ital. Sostanza. Grasse 67, 635-637.
- Oji, O., & Okafor, O. E. (2000). Toxicological studies on stem, bark, leaf and seed kernel of yellow oleander (*Thevetia peruviana*). *Phytotherapy Research*, 14, 133-135. [https://doi.org/10.1002/\(SICI\)1099-1573\(200003\)14:2<133::AID-PTR598>3.0.CO;2-K](https://doi.org/10.1002/(SICI)1099-1573(200003)14:2<133::AID-PTR598>3.0.CO;2-K)
- Oji, O., Madubuike, F. N., & Nwalozie, M. C. (1993). Mortality in rats following dietary inclusion of *Thevetia neriifolia* seeds. *Fitoterapia*, 64, 137-139.
- Oji, O., Madubuike, F. N., Ojmelukwe, P. C., & Ibeh, C. M. (1994). Rodenticide Potential of *Thevetia peruviana* J. *Herbs SPICES MEDICINAL PLANTS*, 2, 3-10. https://doi.org/10.1300/J044v02n03_02
- Omolara, O. O., & Ibiyemi, S. A. (2007). Effect on the nutrient content of *Thevetia peruviana* seed cake. *Res. J. Applied Science*, 2(2), 188-191.
- Pahwa, R., & Chatterjee, V. C. (1990). The toxicity of yellow oleander (*Thevetia neriifolia* juss) seed kernels to rats. *Vet. Hum. Toxicol.*, 32, 561-564. <https://doi.org/10.1080/10915810601163939>
- Plunkett, M., & Signe, J. (2001). Emergency Procedures for the Small Animal Veterinarian. *Harcourt Publishers*. 289-292pp.
- Reed, D. K., Freedman, B., & Ladd, T. L. (1982). Insecticidal and antifeedant activity of *Thevetia neriifolia* against codling moth, striped cucumber beetle and Japanese beetle. *J. Econ. Entomol.*, 75, 1093-1097. <https://doi.org/10.1093/jee/75.6.1093>
- Reitman, S., & Frankel, S. (1957). A colorimetric method for the determination of serum glutamic oxalacetic and glutamic pyruvic transaminases. *Am. J. Clin. Pathol.*, 28, 56-63. <https://doi.org/10.1093/ajcp/28.1.56>
- Roberts, D. M., Southcott, E., Potter, J. M., Roberts, M. S., Eddleston, M., & Buckley, N. A. (2006). Pharmacokinetics of digoxin cross-reacting substances in patients with acute yellow oleander (*Thevetia peruviana*) poisoning, including the effect of activated charcoal: *Therapeutic Drug Monitoring*, 28(6), 784-792. <https://doi.org/10.1097/FTD.0b013e31802bfd69>
- Saxena, V. P., & Jain, S. K. (1990). *Thevetia peruviana* kernel oil: a potential Bactericidal agent. *Fitoterapia*, 61, 348-349. <https://doi.org/10.4236/jbm.2014.26006>
- Schalm, O. W., Jain, N. C., & Carroll, E. J. (1975). Veterinary hematology (3rd ed., p.15-218). USA: Lea & Fabiger, Philadelphia.

Sharma, M., Jain, P., Varanasi, J.L., Lal, B., Rodríguez, J., Lema, J. M., & Sarma, P. M. (2013). Enhanced performance of sulfate reducing bacteria based biocathode using stainless steel mesh on activated carbon fabric electrode. *Bioresour. Technol.*, *150*, 172-180. <https://doi.org/10.1016/j.biortech.2013.09.069>

Shawn, D., & Pearn, J. (1979). Oleander poisoning. *Med. J. Aust.*, *2*, 267-9. <https://doi.org/10.5694/j.1326-5377.1979.tb127135.x>

SMUI (2018). Satellite Map of University of Ibadan, <https://latitude.to/articles-by-country/ng/nigeria/15223/university-of-ibadan>

Space, J. C., Waterhouse, B. M., Miles, J. E., Tiobech, J., & Rengulbai, K. (2003). Report to the Republic of Palau on invasive plant species of environmental concern. USDA Forest Service, Honolulu, 179pp.

Taiwo, B. J., & Igbeneghu, O. A. (2014). Antioxidant and Antibacterial Activities of Flavonoid Glycosides from *Ficus Exasperata* Vahl-Holl (Moraceae) Leaves. *Afr. J. Tradit. Complement. Altern. Med.*, *11*, 97-101. <https://doi.org/10.4314/ajtcam.v11i3.14>

Taiwo, V. O., Afolabi, O. O., & Adegbuyi, O. A. (2004). The effect of *Thevetia peruviana* seed cake- based meal on the growth, haematology and tissue of rabbits. *Tropical and Subtropical Agroecosystem*, *4*, 7-14.

Trepanier, L. A. (2013). Applying pharmacokinetics to veterinary clinical practice. *Vet. Clin. North Am. Small Anim. Pract.*, *43*, 1013-1026. <https://doi.org/10.1016/j.cvs.2013.04.002>

Watt, J. M., & Breyer-Brandwijk, M. G. (1962). The Medicinal and Poisonous Plants of Southern and Eastern Africa. Edinburgh and London, pp. 107-109.

Weinhouse, E., Kaplanski, L., Danon, A., & Nudel, D. B. (1989). Cardiac glycoside toxicity in small laboratory animals. *Life Science*, *44*(7), 441-50 [https://doi.org/10.1016/0024-3205\(89\)90459-1](https://doi.org/10.1016/0024-3205(89)90459-1)

Wilmshurst, J. M., Anderson, A. J., Higham, T. F. G., & Worthy, T. H.. (2008). Dating the late prehistoric dispersal of Polynesians to NewZealand using the commensal Pacific rat. *Proceedings of the National Academy of Sciences*, *105*, 7676-7680. <https://doi.org/10.1073/pnas.0801507105>

Copyright Disclaimer

Copyright for this article is retained by the author(s), with first publication rights granted to the journal.

This is an open-access article distributed under the terms and conditions of the Creative Commons Attribution license (<http://creativecommons.org/licenses/by/4.0/>).