WEST AFRICAN JOURNAL OF MEDICINE

CASE REPORT

Cryptococcal Meningitis in a Newly Diagnosed AIDS Patient: A Case Report

La cryptococcose méningée d'un malade du SIDA nouvellement diagnostiqués: Un rapport de cas

A. K. Salami*[†], J. A. Ogunmodede[†], A. Fowotade[‡], C. Nwabuisi[‡], K. W. Wahab[†], O. O. Desalu[†], A. Fadeyi[‡]

ABSTRACT

BACKGROUND: **Cryptococcus neoformans is a very important cause of fungal meningitis in immunosuppressed patients**

OBJECTIVE: **To describe a case of cryptococcal meningo-encephalitis in an HIV/AIDS patient from the University of Ilorin Teaching Hospital.**

METHODS: **An 18 -year -old male student presented with cough, weight loss, and fever. He was clinically assessed and had full laboratory investigations including cerebrospinal fluid CSF and then started on chemotherapy. Both the clinical and neurological evaluation of the patient was described along with the laboratory analyses of his CSF. Outcome of how he was managed was also reported.**

RESULTS: **Cryptococcus neoformans presented as an AIDS defining fungal infection for the first time in this 18 year old undergraduate who was infected probably from transfusion of unscreened blood He had advanced HIV infection (CD4+ count of 29cells/ul) and severe cryptococcal meningoencephalitis. He was unsuccessfully managed with fluconazole, a second choice drug for this condition, amphotericin B being not available.**

CONCLUSION: **Nigerians should have access to effective blood transfusion services at all public and private hospitals across the country. The National Essential Drug list should be expanded to include drugs such as amphotericin B which hitherto were considered exotic. WAJM 2009; 28(5): 343–346.**

Keywords: **AIDS, Cryptococcus, meningoencephalitis, Case report.**

RÉSUMÉ

CONTEXTE: *Cryptococcus neoformans est une cause très importante de méningite fongiques chez les patients immunodéprimés*

OBJECTIF: *Décrire un cas de méningo-encéphalite cryptococcose chez un patient VIH / sida de l'Université d'Ilorin Teaching Hospital.*

MÉTHODES: *An 18-year-old male étudiant a présenté une toux, perte de poids, fièvre. Il a été cliniquement évaluées et menait des enquêtes de laboratoire complète, y compris le LCR liquide céphalo-rachidien, puis a commencé une chimiothérapie. Dans l'évaluation clinique et neurologique du patient a été décrite avec les analyses de laboratoire de son CCA. Résultat de la manière dont il a été géré a également été rapportés.*

RÉSULTATS: *Cryptococcus neoformans présenté comme une infection fongique qui définissent le SIDA pour la première fois en cette année de premier cycle 18 ans qui a été probablement infectés par la transfusion de sang non testé Il avait une infection à VIH avancée (CD4 + de 29cells/ul) et sévère méningo-encéphalite cryptococcose. Il a été géré sans succès avec le fluconazole, un médicament de deuxième choix pour cette condition, l'amphotéricine B n'est pas disponible.*

CONCLUSION: *Les Nigérians doivent avoir accès aux services de transfusion sanguine efficace dans tous les hôpitaux publics et privés à travers le pays. La liste nationale des médicaments essentiels devrait être élargi pour inclure les médicaments tels que l'amphotéricine B, qui étaient jusqu'ici considérées comme exotiques. WAJM 2009; 28 (5): 343–346.*

Mots-clés: *sida, Cryptococcus, méningo-encéphalite, Case report.*

UNIVERSITY OF IBADAN LIBRARY

Department of [†]Medicine [‡]Medical Microbiology,College of Health Sciences, University of Ilorin, PMB 1515, Ilorin.

***Correspondence:* Dr. Salami AK,** P. O. Box 4470, Ilorin, Nigeria

Abbreviations: CSF, Cerebrospinal fluid; **HAART,** Highly active anti-retroviral therapy; **UITH,** University of Ilorin Teaching Hospital; **HIV,** Human Immunodeficiency Virus.

INTRODUCTION

Cryptococcus neoformans is the most important cause of fungal meningitis in immunocompromised patients worldwide.[1] It often occurs when the CD4+ T cell count is less than 100cells/µL[2]. Cryptococcosis, caused by *C.neoformans* usually follows inhalation of desiccated fungal cells into the lungs. The initial pulmonary infection may remain sub-clinical in immunocompetent subject, but is almost always followed by disseminated disease in HIV infected patients.[3] It has two varieties which differ in their geographical distribution and natural habitats.[1] These are C. *neoformans var. neoformans* and *C. neoformans var. gattii*, both of which have been reported to be capable of causing meningitis in HIV patients.[4,5,6] We report the first case of cryptococcal meningitis from our centre, though other opportunistic fungi such as candidia[7] and scopulariopsis[8] meningitis had earlier been reported in HIV infected patients.

CASE REPORT

An 18-year-old male undergraduate was admitted into the medical ward of the University of Ilorin teaching Hospital UITH Kwara State, North Central Nigeria. He presented with cough of two months duration, progressive weight loss of one month and fever of three weeks duration. Cough was productive of a thick whitish sputum. There was associated chest pain, but no night sweat or history of contact with a case of chronic cough. There was no haemoptysis. Weight loss was gradual, progressive and associated with a reduced appetite. Fever was high grade, intermittent, and associated with chills and rigors. There was headache that was generalised, non-throbbing, without photophobia, phonophobia, dizziness, or convulsion.

He had a history of blood transfusion during a febrile illness that was associated with anaemia in a private hospital about five years before presentation. Further information on this febrile illness was scanty; however, the transfused blood was obtained from a regular paid donor. His Hb electrophoresis pattern was AS. There was no history of prior surgery, abuse of intravenous drugs, or history of sharing of sharps with other people. He denied being sexually active.

Physical examination revealed a young man who was drowsy, febrile (temperature 38.9°C). He was chronically ill looking, pale with generalized lymphadenopathy. He had neck stiffness with positive Kernig's and Brudzinski's signs. He had left sided 7th cranial nerve palsy, with normal motor function. The pupils were equal in size with good light reflex but fundoscopy showed engorged retinal vessels and swollen optic discs. His respiratory rate was 20 cycles per minute and he had bronchial breath sounds in the left middle and lower chest zones posteriorly. His arterial pulse rate was 86 beats per minute regular, full volume, blood pressure was 100/60 mmHg and his apex beat and hearts sounds. were normal. The other systems were essentially normal.

A tentative diagnosis of disseminated tuberculosis with lung and meningeal involvement was made while undergoing a diagnostic workup. Twenty percent mannitol at a dose of 250mls was infused over 30minutes before lumbar puncture was cautiously done with a 23-gauge needle; 5mls of clear and colourless cerebrospinal fluid (CSF) was withdrawn. Equal volume of normal saline was instilled back into the spinal canal.

He was HIV sero-positive with a $CD4^+$ cell count of 29cells/µl. CSF protein was 10mg/dL, sugar; 1.9 mmol/L, and casual blood sugar was 6.9mmol/L. No organism was seen on gram stain. The CSF cell count showed few red blood cells but no white blood cell. Microscopic examination of the CSF sediment after centrifugation at 3000rpm for 5minutes and mixing with equal volume of Indian ink revealed a structure characteristic of cryptococcal organism,[9,10] (Figure 1).

There was no growth on both blood and chocolate agar plates inoculated with CSF sediment and incubated at 37°c aerobically and in a carboxyphillic environment for 24 hours respectively. However, culture of CSF on saboraud agar incubated aerobically at 37°C for seven days gave a growth typical of cryptococcal neoformans.[11] This was first noticed on the 4th day of incubation. The isolate appeared as large gram positive cocci which were germ tube negative but phenol oxidase positive and rapidly hydrolyzed urea, which are characteristics of *Cryptococcus spp.*

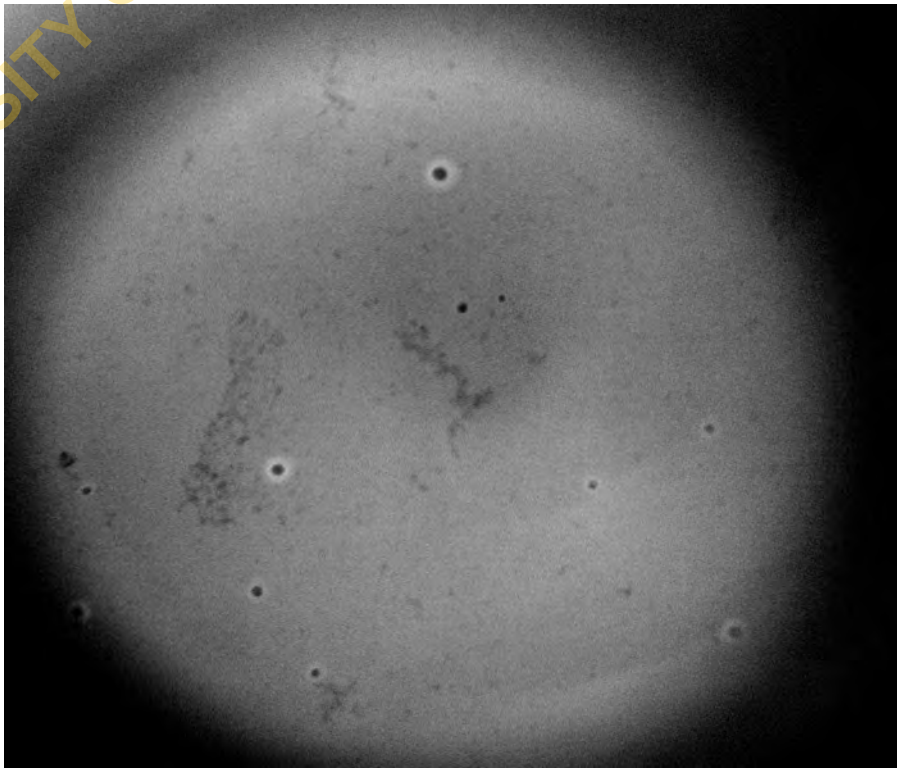

Figure 1: Indian ink positive cells of cryptococcal organism in the patient's CSF NB: *Cryptococcus neoformans,* are seen above as black dots with a rim of halo.

UNIVERSITY OF IBADAN LIBRARY

He was started on intravenous cefuroxime 750mg 8hourly, which was stopped after the diagnosis of cryptococcal meninigoencephalitis was made. He was then commenced on intravenous fluconazole 200mg daily due to the non-availability of amphotericin B. He was also commenced on oral highly active anti-retroviral therapy (HAART) comprising Stavudine 30mg, lamivudine 150mg, and nevirapine 200mg all twice daily. However, the patient's clinical state deteriorated and he died three days after the initiation of both fluconazole and anti-retroviral therapies. He possibly died from the overwhelming cryptococcal meninigoencephalitis in the presence of severe immune suppression.

DISCUSSION

Cryptococcus *neoformans* is one of the commonest opportunistic infections responsible for life threatening complications of AIDS in Africa. In recent times, the incidence of cryptococcal meningitis in patients infected with HIV has increased worldwide mainly because of the increased awareness on the part of both the physicians and clinical microbiologists.[12] It generally occurs when the $CD4^+$ T cell count is less than 100cells/ µl and presents in descending order as cryptococcal meningitis, pulmonary *cryptococcosis* and cryptococcosis of the skin.

The index case of this report presented typically with meningo-encephalitic features as evident by neck stiffness, a lateralizing sign (left sided 7th cranial nerve palsy) and alteration of sensorium. Perhaps the consolidation on his left lung coupled with the pulmonary infiltrates demonstrated on his chest radiograph were signs of cryptococcal pneumonitis. However, his sputum was negative on culture for fungal spores and we did not have facilities for detecting cryptococcal capsular antigen in patient's body fluid/tissue specimens by latex agglutination technique. However, the organism was demonstrated on culture of CSF and this was also Indian ink smear positive. In this case cryptococcal meningoencephalitis manifested as an AIDS defining illness. And in keeping with our previous report[13] of infectious opportunistic diseases occurring at a very low $CD4^+$ cell count in AIDS patients, the patient had a count of 29cells/ul. This is the first case to be reported from this centre because of the dearth of appropriate microbiological diagnostic facilities in this hospital. Suffice to say that such facility was only recently acquired.

The best treatment could however, not be offered to the patient as he was managed with intravenous fluconazole because of the non availability of amphotericin B, which has been proven to be more efficacious than fluconazole in the primary treatment of cryptococcal meningitis in patients with AIDS.[14,15]

The outcome of treatment was, therefore, not surprisingly poor, partly because the drug of first choice was unavailable and partly because the patient had from outset some of the indices[16-18] of a bad prognosis. The advanced nature of the immunosuppression, the severity of the complicating illness that presented with an abnormal mental status at diagnosis and the pretreatment Indian ink positive CSF as well as the absence of white blood cells in his CSF are all indication of poor prognosis.

This case clearly illustrates the importance of effective blood transfusion services at all public and private hospitals across the country, and inclusion of some drugs which hitherto have been considered exotic in our national essential drug lists. Such drug is amphotericin B.

REFERENCES

1. Yimtubezenash WA, Leykun J, Dawit A. Isolation and characterization of Cryptococcus neoformans from environmental sources in Ethiopia. *Ethiopian Journal of Health Development.* 2001; **15:** 45–49.
2. Fauci AS, Lane HC. Human Immunodeficiency Virus Disease: AIDS and Related Disorders in Fauci AS, Kasper DL, Braunwald E, Hauser SL, Longo DL, Jameson JL. Harrison's Principles of Internal Medicine, 17th ed. McGraw-Hill Companies, New York. 2008. p. 1137–1204.
3. Hoffmann C. Cryptococcosis in Hoffmann C Jürgen K. Rockstroh JK, Kamps BS, HIV Medicine, 15th ed. Flying Publishers, Paris. 2007. p. 452–456.
4. Karstaedt AS, Crewe-Brown HH, Dromer F. Cryptococcal meningitis caused by Cryptococcal neoformans var gatti, serotype C in AIDS patients in Soweto, South Africa. *Med Mycol.* 2002. p. 7–11.
5. Nagarajan S, Gugnani HC, Kowshik T. Case report. Meningitis due to Cryptococcus neoformans var. neoformans serotype AD associated with pulmonary tuberculosis. *Mycoses.* 2000. p. 67-69.
6. Bodasing N, Seaton RA, Shankland GS, Kennedy D. Cryptococcus neoformans var. gatti in an HIV-positive patient: first observation in the United Kingdom. *J Infect.* 2004; **49:** 253–5.
7. Sanya EO, Amen NB, Onile BA. Candida meningitis in immunosuppressive patient. A case report. *West Afr J Med.* 2006; **25:** 79-80
8. Salami AK, Nwabuizi C, Abdullahi NA, Agbede OO. Scopulariopsis associated meningitis in adult Nigerian aids patient. *West Afr J Med.* 2003; **22:** 64–65.
9. Washington Winn jr. Allen , Janda W. Koneman E. Mycology in Koneman's color atlas and textbook of diagnostic microbiology. 6th ed. Lippincott Williams and Wilkins. 2006. p.1151–1245.
10. Warren, NG, Hazen KC. Candida, cryptococcus and other yeasts of medical importance In: Murray PR, Baron JOE, Jorgensen SH, Pfaller MA. *Manual of Clinical Microbiology.* 6th ed. ASM. Washington DC. 2005. p. 723–737.
11. Monica cheesbrough. Medical laboratory manual for tropical countries, 2nd ed. Butterworth & Co, Cambridge. 1984. p.390-391.
12. Ashiru JO, Aleong K. Cryptococcal meningitis in patients with Human Immunodeficiency Virus infection: report of three cases. *African Journal of Clinical and Experimental Microbiology.* 2005; **6:** 257–260.
13. Salami AK , Olatunji PO and Oluboyo PO. Spectrum and prognostic significance of opportunistic diseases in HIV/AIDS patients in Ilorin, Nigeria. *West Afr J Med.* 2006; **25:** 52–56.
14. Galgiani JN. Fluconazole. a new antifungal agent. *Ann Intern Med.*1990; **113:** 177–179.
15. Larsen RA, Leal MAE, Chan LS. Fluconazole compared with amphotericin B plus flucytosine for cryptococcal meningitis in AIDS. *Ann Intern Med* 1990; **113:** 183–187.
16. Joseph AK, Andrea AK, Michael P, Craig W, Vee JG, Carmelita U *et al*. Cryptococcosis in the acquired immunodeficiency syndrome. *Ann Intern Med.* 1985;**103:** 533–538

UNIVERSITY OF IBADAN LIBRARY

17 Zuger A, Louie E, Holzman RS, Simberfoff MS, Rahal JJ. Cryptococcal diseases in patients with the acquired immunodeficiency syndrome. *Ann Intern Med.* 1986; **104:** 234–240.

18 Dismukes WE, Cloud G, Gallis HA, Kerkering TM, Medoff G, Craven PC *et al.* treatment of cryptococcal meningitis with combination amphotericin B and flucytocine for four as compared to six weeks. *N Engl J Med.* 1987; **317:** 334–341.

UNIVERSITY OF IBADAN LIBRARY